

TEXAS FETAL CENTER NEWSLETTER

March 2013 • 3rd Edition

*The Texas Fetal Center at Children's Memorial Hermann Hospital, in collaboration with
The University of Texas Health Science Center at Houston (UTHealth) Medical School.*

Congenital Diaphragmatic Hernia: More Than Repairing a Hole

The management and treatment of congenital diaphragmatic hernia (CDH) remains a challenge for all clinicians. Despite advances in prenatal diagnosis, surgical treatment and neonatal critical care, infants born with CDH still accrue a significant mortality and long-term disability. The morbidity and mortality associated with CDH is largely due to pulmonary hypoplasia and pulmonary vascular hypoplasia/hypertension as well as its associated anomalies. Over the last 25 years, clinical efforts to avoid lung injury, including extracorporeal membrane oxygenation (ECMO), high-frequency oscillation ventilation (HFOV), and ventilation strategies, have improved overall survival rate, but there remains significant variation among institutions with an overall survival of only 72 percent*.

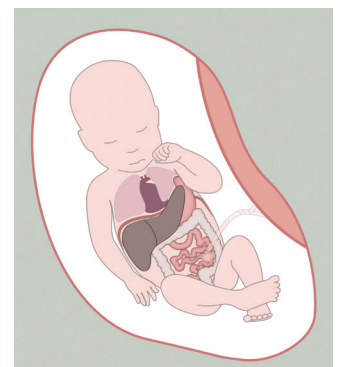
In the last two decades, the CDH team at Children's Memorial Hermann Hospital and The University of Texas Health Science Center at Houston (UTHealth) Medical School has been dedicated to providing the most comprehensive and state-of-the-art care for newborns with CDH. The management of infants with CDH is directed by a comprehensive and highly experienced team of affiliated specialists, including maternal-fetal specialists, neonatologists and pediatric surgeons. The fully integrated continuum of care program begins with prenatal diagnosis using the most advanced fetal ultrasound, echocardiography and MRI, in order to provide families and practitioners with the most accurate predicted prognosis. The multidisciplinary team collaborates together on a coordinated delivery plan for the infant in order to provide a smooth transition from prenatal to postnatal life.

In the last 20 years, the Neonatal Intensive Care Unit (NICU) at Children's Memorial Hermann Hospital has successfully cared for the most severe infants with CDH. The hospital's neonatal ECMO program was the first in Texas and has the most experienced team in the region. In addition, a long-standing, aggressive, surgical approach to the care of CDH babies has resulted in the fewest number of infants without surgical repair, meaning almost every CDH infant is approached as a possible survivor, regardless of associated anomalies or pathophysiology. As a result of this integrated strategy, the hospital's risk-adjusted outcomes for CDH patients are in the top 15 percent worldwide with markedly lower-than-expected pulmonary morbidity* and this protocolized approach has been adopted by many international institutions.

The care of infants with CDH does not stop at the bedside. Scientists and researchers at UTHealth Medical School, as part of the CDH integrated program, continue to address critical clinical care issues. The Medical School is the home of the Congenital Diaphragmatic Hernia Registry, the largest research database for CDH. Developed and led by Kevin P. Lally, M.D., M.S., surgeon-in-chief at Children's Memorial Hermann Hospital and chair of the department of Pediatric Surgery at UTHealth Medical School, the Congenital Diaphragmatic Hernia Study Group is an international consortium of data on more than 7,000 babies with the condition. The advanced fetal and neuroimaging program is studying ways to refine the diagnosis of CDH and its associated neurological sequelae in order to treat the condition either before or after delivery. The fetal intervention research group is developing novel techniques for fetal tracheal occlusion in order to promote antenatal lung growth. Also, the Children's Regenerative Medicine Program at UTHealth Medical School is developing cellular-based therapies to treat CDH and ECMO associated neurological injuries and lung growth, as well as autologous diaphragmatic replacement patches from autologous amniocyte stem cells.

For more information about the fully integrated Congenital Diaphragmatic Hernia Program at Children's Memorial Hermann Hospital, please contact the Texas Fetal Center at 832.325.7288 or visit us at texasfetalcenter.org.

*Data from the Congenital Diaphragmatic Hernia Registry





Ongoing Research Projects

Ramesh Papanna, M.D., a visiting fellow from Yale School of Medicine, has spearheaded an ongoing swine project at The University of Texas Health Science Center at Houston (UTHealth) Medical School to study various methods for sealing iatrogenic defects at fetoscopy. He and Kenneth Moise, Jr., M.D., serve as co-investigators on an NIH grant submitted to the National Institute of Child Health & Human Development (NICHD) by the principal investigator, Russell Stewart, Ph.D., a bioengineer from the University of Utah. The grant received a favorable score on its initial submission; a re-submission has received an excellent score and funding will likely begin in July 2013.

A sheep project has been approved by the Animal Welfare Committee at UTHealth Medical School to complete the initial evaluation phase of a novel engineered balloon for the treatment of fetal diaphragmatic hernia. The principal investigator, Anthony Johnson, D.O., began initiating experiments in February 2013.

A second sheep project to study minimally invasive fetal repair of myelomeningocele has been approved by the UTHealth Medical School's Animal Welfare Committee and is scheduled to begin in the spring of 2013. The project will involve the use of a novel under-water glue developed by Russell Stewart, Ph.D., of the University of Utah.

In Print and Publication

Argoti PS, Bebbington M, Johnson A, Moise KJ. The indirect pump: The unique presentation of a monochorionic-triamniotic triplet gestation complicated by TRAP sequence successfully managed with radiofrequency ablation of the acardiac fetus. *Ultrasound Obstet Gynecol* (pre-pub online).

Moise KJ, Argoti P. Importance of determination of chorionicity in twin gestations. *Contemp Ob Gyn* 2013;58:35-43.

Moise KJ, Argoti P. Management and prevention of red cell alloimmunization in pregnancy: A systematic review. *Obstet Gynecol* 2012; 120:1132-9.

Moise KJ Jr, Boring NH, O'Shaughnessy R, Simpson LL, Wolfe HM, Baxter JK, Polzin W, Eddleman KA, Hassan SS, Skupski D, McLennan G, Paladino T, Oeth P, Bombard A. Circulating cell-free fetal DNA for the detection of RHD status and sex using reflex fetal identifiers. *Prenatal Diagn* 2013;33:95-101.

Presentations

The Texas Fetal Center at The University of Texas Health Science Center at Houston (UTHealth) Medical School and Children's Memorial Hermann Hospital has collaborated with the fetal Centers at Yale School of Medicine, Children's Hospital of Philadelphia, University of Maryland and Cincinnati Children's Hospital. This collaboration has resulted in several abstracts that were presented at the 33rd Annual Meeting of the Society for Maternal-Fetal Medicine in San Francisco.

Argoti P, Papanna R, Bebbington MW, Khalek N, Baschat A, Johnson A, Moise KJ. Outcomes of laser photocoagulation for fetofetal transfusion syndrome in dichorionic-triamniotic triplet gestations as compared to monochorionic-diamniotic twins.

Papanna R, Mann LK, Block-Abraham D, Buhimschi I, Bebbington MW, Garcia EI, Khalek N, Harman CR, Moise Jr. KJ, Baschat A, Johnson A. Predictors of preterm delivery after fetoscopic laser surgery for twin-twin transfusion syndrome.

Papanna R, Mann LK, Moise Jr. KJ, Kyriakides T, Zhao G, Argoti P, Buhimschi CS, Buhimschi IA. Amniochorion apoptosis and autophagy: novel insights into the mechanisms of PPRM after fetoscopic laser surgery for twin-twin transfusion syndrome.

Papanna R, Mann LK, Johnson A, Moise K, Moise Jr. KJ. Chorioamnion plugging with absorbable gelatin sponge to prevent iatrogenic preterm premature rupture of membranes after fetoscopic laser surgery for twin-twin transfusion syndrome.

Spina Bifida Program: Providing Coordinated and Compassionate Care

Following the publication of the NIH-sponsored Management of Myelomeningocele Study (MOMS) trial results in the *New England Journal of Medicine* more than 18 months ago, the Texas Fetal Center (TFC) began a program offering open fetal surgery, in selected cases, for fetuses with myelomeningocele (MMC). At the Texas Fetal Center, patient consultation for a diagnosis of MMC involves a multidisciplinary team not only for evaluation but also for surgery. The team draws on the expertise of multiple medical, surgical and support teams to offer a top quality experience for all families.

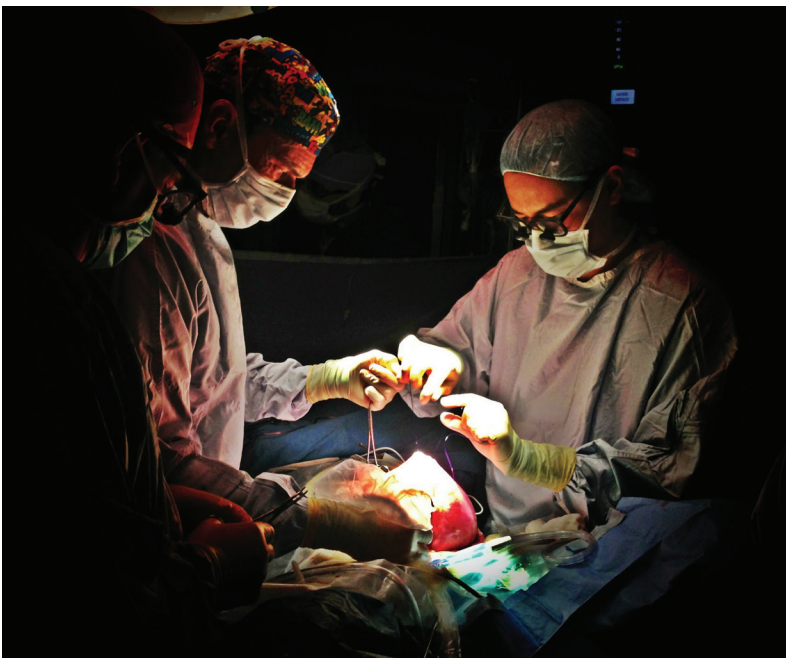The Texas Fetal Center team follows the same medical criteria that were used in the MOMS Trial when evaluating patients for possible open fetal repair. Families spend two days at our Center meeting with the multidisciplinary team, including the fetal specialists, clinical coordinator, neonatal team, pediatric neurosurgeon, pediatric surgeon and a representative of the Spina Bifida Clinic at Shriner's Hospital. Patients also undergo an extensive evaluation including a comprehensive ultrasound, fetal MRI, and fetal echocardiography.

To ensure a smooth and comfortable experience, the Texas Fetal Center has a team of concierge coordinators that assist with directions, parking, information, scheduling and guiding families throughout the hospital. After the full two-day consultation, patients who are candidates for surgery are encouraged to go home and weigh the pros and cons for open fetal surgery versus post natal repair in order to make the best decision for their family, based on the information received.

Since the establishment of the Spina Bifida Program in early 2011, our team has evaluated more than 36 families and performed nine successful surgeries. One difference from the MOMS trial that has been helpful to our families is allowing them to return to their home community once their postoperative recovery is complete. This option exists as long as their medical condition is not complicated and their local physician is willing to care for them in their home community. We still recommend that families return to the Texas Fetal Center for their delivery to provide continuity of postnatal care.

For more information about open fetal surgery for fetal MMC repair or to refer a patient for an MMC evaluation, contact the Texas Fetal Center at 832.325.7288 or toll free at 888.818.4818.

Visit texasfetalcenter.org/spina-bifida to view our patient care algorithms as well as an education video about spina bifida and fetal intervention.



(From left to right) Fetal intervention specialists, Kenneth Moise, Jr., M.D., and Michael Bebbington, M.D., along with KuoJen Tsao, M.D., pediatric surgeon, collaborate together for an open fetal repair of MMC.

Anthony Johnson, D.O. Appointed to the NAFTNet Executive Committee



Anthony Johnson D.O., has been elected to the executive committee of the North American Fetal Therapy Network (NAFTNet). He is joined by three other NAFTNet members who were elected by their peers from a group of 46 eligible candidates. Dr. Johnson's recent appointment reinforces the Texas Fetal Center's mission of continuing actively participate in the study of the natural history of fetal diseases and in the research and development of therapeutic prenatal interventions to improve outcomes.

As one of the founding members of NAFTNet, Dr. Johnson was instrumental in obtaining funding for the organization from the National Institutes of Health (NIH) and served as the network's secretary treasurer from 2005 to 2010. After his term ended, he remained active in the network as one of the ad hoc NAFTNet members to the National Institute of Child Health and Human Development's (NICHD) Task Force to develop minimum criteria for the centers that are considering the option of open fetal surgery for the repair of fetal myelomeningocele (fMMC). Establishing these criteria is essential in order to ensure optimal maternal and fetal/pediatric outcomes, to optimize patient safety and to advance the knowledge of the role and benefit of fetal surgery in the management of fMMC following the publication of a randomized trial of prenatal versus postnatal repair of myelomeningocele (N Engl J Med.2011, Mar 17;364(11).

The Texas Fetal Center is one of five fully integrated fetal centers in the country and is the most experienced fetal program in the southwest United States. With Dr. Johnson's return to the NAFTNet leadership, the Texas Fetal Center will remain on the forefront in the development of therapeutic prenatal interventions to improve maternal and fetal outcomes in high-risk pregnancies affected by fetal disease.

For more information about the North American Fetal Therapy Network, visit naftnet.org.



Texas Fetal Center Patient Story

Super Girl, Baby Brianna

Jeanette learned she was pregnant with her third child while she was serving on active duty and although the pregnancy was unplanned, she was excited about having another baby. Her 18-week ultrasound revealed a healthy little girl she named Brianna. As the weeks progressed, she noticed Brianna was not moving quite as much as her previous two daughters did throughout pregnancy. A routine ultrasound was scheduled at 26 weeks' gestation to evaluate fetal growth and, unexpectedly, gross fetal hydrops was detected.

As a busy mother of two, Jeanette remembers her daughters playing with a neighbor's child who was later diagnosed with fifth disease, a viral infection caused by parovirus B19. Jeanette did not make much of this because neither she nor her daughters experienced any of the typical signs of the illness, which include fever and apparent skin rash.

Soon after the fetal diagnosis was made, Jeannette was referred to the Texas Fetal Center (TFC) and arrived the next day. On initial assessment, a severely hydropic fetus was found with cardiomegaly, an enlarged heart, complicated by severe mitral and tricuspid regurgitation as well as scalp edema, pericardial effusion and significant ascites. Further evaluations were performed to better assess both Jeannette's and Brianna's health.

A Doppler examination of Brianna's middle cerebral artery revealed a peak systolic velocity, indicating severe fetal anemia. In addition, a maternal anti-red antibody screen was negative, the RPR was nonreactive and a Kleihauer-Betke stain was negative for a fetomaternal hemorrhage.

Jeannette was told the most probable diagnosis was fetal parvovirus infection but there was not enough time to confirm the diagnosis if her little girl was to be saved. Although the fetal anemia could be corrected with an emergency intrauterine transfusion, Jeanette knew the risks to baby Brianna: she might not survive or could later develop cerebral palsy.

Jeannette decided she could not give up on her unborn child and an emergency intrauterine transfusion was performed at Children's Memorial Hermann Hospital later that day. The fetal hematocrit was only 4.8 percent and the platelet count was 26,000. Although donor red cells were easily infused into the fetal umbilical cord, prolonged bleeding from the puncture site resulted in the loss of most of the new red cells. The fetal karyotype by FISH was normal but fetal blood and amniotic fluid was positive for parvovirus B19 by PCR.

More intrauterine transfusions were undertaken over the next five days. Each was complicated by prolonged bleeding after the needle was removed from the umbilical vein. This occurred despite the infusion of platelets along with the red cells. Another middle cerebral artery Doppler procedure was performed the following day, which revealed continued severe fetal anemia.



Texas Fetal Center Patient Stories

Super Girl, Baby Brianna *(continued)*

Jeannette and the fetal medicine specialists were all frustrated – what else could be done? A decision was made to attempt one last transfusion using a much smaller, needle. Infusing the donor red cells and platelets through the small needle would be a challenge but it was hoped the smaller puncture would reduce bleeding problems. The procedure went well but when the needle was removed, bleeding again ensued. Ultimately, the surgeons were able to stop the bleeding by compressing the umbilical cord against the placenta using the ultrasound transducer.

Baby Brianna did well after this last procedure. Her Dopplers remained normal, the anemia did not recur and the hydrops completely resolved. Jeannette was induced at 37 weeks' gestation and baby Brianna was born weighing 5 pounds, 7 ounces. A team of neonatologists from The University of Texas Health Science Center at Houston (UTHealth) Medical School was on standby throughout the delivery to step in if needed, but Brianna came out pink, healthy and screaming. She stayed in the hospital for two days and went home.

Jeannette and Brianna's care represents the true spirit of collaboration between the Texas Fetal Center at UTHealth Medical School and Children's Memorial Hermann Hospital, which included a team of nurse coordinators, labor and delivery and OR nurses, fetal medicine specialists, neonatologists, anesthesiologists, blood bank representatives, laboratory technicians and sonographers. Without the hard work and persistence of these individuals, Brianna would not be here to share her life with her older sisters.

To contact the Texas Fetal Center, call 832.325.7288 or toll free at 1.888.818.4818. For more information, visit texasfetalcenter.org.

Texas Fetal Center Events

Texas Two-Step Conference: Improving Maternal and Fetal Care

Michael Bebbington, M.D., and Baha Sibai, M.D., served as co-directors for the 3rd annual Texas Two Step Conference: Improving Maternal and Fetal Care, which was held at the Westin Houston at Memorial City on Friday and Saturday, January 11 and 12, 2013. More than 180 attendees from across the state gathered for the two-day interactive conference, which provided physicians, nurses, sonographers, midwives and other prenatal healthcare providers with the latest updates in the state-of-the-art advances in detecting, evaluating and treating high-risk pregnancy conditions and selective fetal anomalies.

Dr. Bebbington kicked off the conference on Friday, January 11 with a full agenda of fetal topics, including the management of multiple gestations; paradigm shifts in prenatal diagnosis; open fetal surgery for spina bifida repair; progesterone therapy and preterm labor; imaging modalities in the diagnosis of congenital heart defects; and current recommendations for ultrasound in early detection of fetal anomalies. Julie Moldenhauer, M.D., assistant professor, department of Surgery at Perelman School of Medicine at the University of Pennsylvania, was the featured speaker for the day and presented Ultrasound and MRI – Complementary Tools in Evaluating Fetal Anomalies. Friday's conference ended with a complimentary cocktail reception thanking all guests for attending the third annual continuing education event.

Dr. Sibai led Saturday's conference, which included high-risk pregnancy topics such as cardiac disease, pulmonary disease, postpartum hemorrhage, thyroid disorders, and management of gestational and type-2 diabetes in pregnancy. John Barton, M.D., director, maternal-fetal medicine at Central Baptist Hospital in Lexington, Ky., was the featured speaker. His lecture topics included Hypertension in Pregnancy: New ACOG Guidelines and Severe Sepsis: and Septic Shock in Pregnancy.

We would like to thank our friends from The University of Texas Medical Branch at Galveston who presented at this year's conference, as well as our colleagues in the division of Maternal-Fetal Medicine at The University of Texas Health Science Center at Houston (UTHealth) Medical School.

We would also like to offer our thanks to Glenveigh Medical LLC and Sequenom Center for Molecular Medicine for the educational grants provided to support this educational activity, and to Community Health Choice, GE Healthcare, Glenveigh Medical, LLC, Hologic, Houston Fertility Institute, and Sequenom Center for Molecular Medicine for exhibiting at our conference.

To download a pdf of the topics presented at this year's conference, visit childrens.memorialhermann.org/cme. If you would like future communication about upcoming education events, email texasfetalcenter@memorialhermann.org.

Upcoming Events:

American Institute of Ultrasound in Medicine (AIUM) Annual Convention

April 6-10, 2013, New York, NY

Stop by exhibit #121 to speak with team members from the Texas Fetal Center.

Management of Multiples: A Multidisciplinary Update

Presented by UTHealth Medical School

Saturday, May 11, 2013 • 8 a.m. - 4 p.m.

The Brown Foundation Institute of Molecular Medicine for the Prevention of Human Diseases (IMM)

Texas Medical Center

Memorial Hermann Healthcare System



7737 Southwest Freeway, Suite C-25
Houston, TX 77074-9777

memorialhermann.org

Nonprofit Org.
U.S. POSTAGE

PAID

Permit No. 3156
Houston, TX



Texas Fetal Center
6410 Fannin, Suite 210
Houston, TX 77030
texasfetalcenter.org