

THE FETAL CENTER NEWSLETTER

Spring 2016 • 9th Edition

*The Fetal Center at Children's Memorial Hermann Hospital in collaboration
with John P. and Kathrine G. McGovern Medical School at UTHealth*

Contents

FEATURE

**Congenital Diaphragmatic
Hernia Update** 1

PATIENT STORIES 4

NEWS OF NOTE 6

Ways to Give to The Fetal Center

Help us continue to provide the highest level of specialized care to both mothers and babies and support the groundbreaking work of The Fetal Center.

For more information on how to support The Fetal Center, visit

[childrens.memorialhermann.org/
the-fetal-center/donate](http://childrens.memorialhermann.org/the-fetal-center/donate)



[Twitter.com/TheFetalCenter](https://twitter.com/TheFetalCenter)



[Facebook.com/TheFetalCenter](https://facebook.com/TheFetalCenter)

Congenital Diaphragmatic Hernia: Physicians and Researchers Improve the Odds Prenatally, Postnatally and Beyond

Congenital diaphragmatic hernia (CDH) remains an unsolved problem and a frustrating clinical disease for physicians, surgeons and scientists despite decades of research. Although it is a surgically correctable defect, the arrest in development of the lungs prenatally results in unacceptably high rates of neonatal mortality and long-term morbidity for the surviving child.

Attempts to improve outcomes in CDH-affected babies through prenatal interventions have been under way for more than 25 years. "In the late 1980s fetal surgeons demonstrated a high survival rate with open maternal-fetal surgery to repair the diaphragmatic defect when the liver was not herniated into the chest. In these cases outcomes were no better than what was seen with treatment after the baby was born," says Anthony Johnson, D.O., professor in the division of Maternal-Fetal Medicine and the department of Pediatric Surgery at the John P. and Kathrine G. McGovern Medical School at UTHealth, co-director of The Fetal Center, and the immediate past president of North American Fetal Therapy Network (NAFTNet). "In the more severe cases, when the liver was herniated into the fetal chest, returning the liver to the abdomen and repairing the defect led to fetal death in many cases due to occlusion of blood flow from the umbilical vein. Prenatal intervention through open maternal-fetal surgery for CDH was subsequently abandoned. Later, research in animal models gave us a fortuitous finding: if the trachea is plugged, the fluid produced in the lungs will build up, with the increased airway pressure causing the lungs to expand and mature. Additionally, the increased growth of the lungs will gradually return the herniated organs back to the abdomen, thereby reducing the risk of pulmonary hypoplasia. Various attempts were made to use mechanical devices to close the trachea."

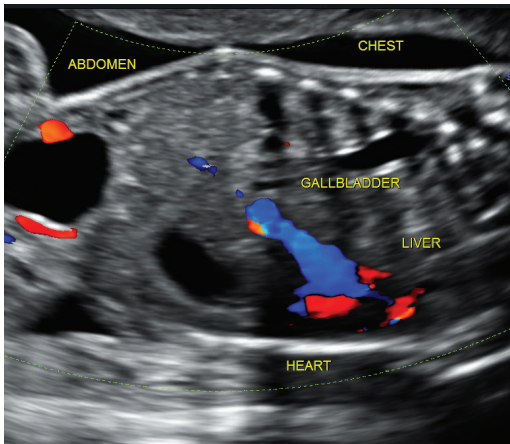
Among these devices was a detachable balloon that could be placed using a telescope (fetoscope) through a small incision in the maternal abdomen, to reduce risk to the mother. In a randomized, controlled trial conducted at the University of California, San Francisco, from April 1999 to July 2001, researchers compared tracheal occlusion using the balloon with standard care. The results, which were published in the *New England Journal of Medicine* in 2003, showed that tracheal occlusion did not improve survival or morbidity rates in the chosen cohort of fetuses.¹ Secondary analysis of this study found that the majority of prenatally treated patients would not have been considered severe or lethal CDH cases based on prenatal ultrasound findings. The trial was not conclusive for fetuses that would be considered at greatest risk.

In a later report from European studies using a similar tracheal balloon but with smaller fetoscopes to further reduce maternal complications, fetal tracheal occlusion (FETO) doubled the survival rate – from 25 to 50 percent – in severe cases of CDH and reduced morbidity as well.²

**Children's
MEMORIAL
HERMANN**
Hospital

continued

Congenital Diaphragmatic Hernia Update



When the study found that FETO might improve neonatal survival in cases with isolated severe CDH, NAFTA led the charge to extend the trial to the United States. Seven fetal centers, including The Fetal Center at Children’s Memorial Hermann Hospital, qualified to participate in the clinical trial, called Tracheal Occlusion to Accelerate Lung Growth (TOTAL) for Severe Pulmonary Hypoplasia. The Fetal Center is now accepting patients for evaluation as study participants.

“With improved prenatal detection through ultrasound and MRI imaging and the use of smaller devices, the appropriate cases can be selected to study the benefits of tracheal occlusion in more severe cases with minimal risk to the mother,” Dr. Johnson says. “Fetuses with a lung-to-head ratio (LHR) of less than 1 and liver herniation have a survival rate of only 10 to 20 percent. The TOTAL Trial looks at this group and examines whether we can improve the outcome with tracheal occlusion.”

Randomization to the study arm is done prior to 27 weeks. The balloon is placed at 27 weeks 0 days to 29 weeks 6 days and removed between 34 weeks 0 days and 34 weeks 6 days due to the risk of rupture and premature labor. Inclusion criteria are mothers ages 18 to 50 years with a singleton pregnancy, isolated left-sided diaphragmatic hernia with an LHR of less than 1 with liver up, normal chromosomes and willingness to live within 30 minutes of Children’s Memorial Hermann Hospital.

Because of the relatively low frequency at which CDH occurs, there have been few randomized, controlled trials involving infants or fetuses with the defect. One in every 2,500 infants is born with CDH independent of race, quality of prenatal care and socioeconomic factors. Its cause remains unknown, and because each case is different, there is no normal recovery time and no standard plan of postnatal care. Thanks to more accurate prenatal diagnosis and the work of the International Congenital Diaphragmatic Hernia Registry, which resides at Children’s Memorial Hermann Hospital and McGovern Medical School, the global survival rate of infants born with CDH is on the rise.

“We continue to make progress in the management of diaphragmatic hernia with mechanical ventilation, pharmacotherapy and other therapeutic modalities, including extracorporeal membrane oxygenation (ECMO),” says Kevin P. Lally, M.D., M.S., FACS, professor and chair of the department of Pediatric Surgery at McGovern Medical School, who has published more than 70 peer-reviewed articles about basic science and clinical research on CDH. “Overall, worldwide survival of infants born with diaphragmatic hernia has increased from about 55 percent to close to 70 percent in the last 20 years. Unfortunately, we still have a significant problem in the short- and long-term management of the most high-risk babies.”

In the 20 years since Dr. Lally helped found the CDH Study Group and the CDH Registry, the voluntary collaborative has gathered data on more than 9,000 babies with diaphragmatic hernia. The registry now represents centers in 14 countries. Advances in prenatal imaging have enhanced visualization of the anatomy of the fetus, providing specialists with more information for treatment decision-making, and about 20 CDH Study Group projects are using the registry’s data to evaluate diagnostic and prognostic variables such as preductal oxygen saturation, defect size/anomaly association and pulmonary hypertension.

“The mortality rate associated with CDH varies widely among fetal centers and still remains relatively high despite the availability of new therapeutic modalities,” Dr. Lally says. “It’s also important to note that many of the new therapies have been implemented without properly controlled studies.”

Most infants with CDH become symptomatic in the first few hours after birth and require endotracheal intubation and mechanical ventilation. In more complicated cases, other therapeutic modalities such as high-frequency oscillatory ventilation, inhaled nitric oxide and ECMO may provide significant benefits for selected infants.

“Some of these kids are so ill that many centers deem them unsalvageable,” Dr. Lally says. “We don’t do that. We take a very aggressive approach to the management of diaphragmatic hernia, and are one of two centers in the country that operate on 93 percent of all patients. Based on risk-adjusted data our outcomes are in the top 10 percent or higher. Except for a few obvious cases, we don’t make the call that a baby is too high risk to save. If blood gas values are really unfavorable early on, we’ll put the baby on ECMO. Our entire team works together to save the baby’s life.”

Congenital Diaphragmatic Hernia Update

Once respiratory stability has been established, which may take days or weeks, surgical repair of the hole in the diaphragm is possible in most cases. “Surgery returns the abdominal organs to the abdominal cavity and makes room in the chest for the hypoplastic lung to grow,” says KuoJen Tsao, M.D., co-director of The Fetal Center at Children’s Memorial Hermann Hospital, secretary/treasurer of NAFTNet and an associate professor in the department of Pediatric Surgery at McGovern Medical School. “But diaphragmatic hernia is not just a hole in the diaphragm. It’s an embryonic defect with many facets. Along with the underdevelopment of lung tissue itself, the lung vasculature is compromised. When these kids die, they die of pulmonary hypertension as well as pulmonary hypoplasia. If they survive, both can cause long-term problems. From the prenatal period on, that’s our biggest challenge. We can assess how much pulmonary hypoplasia they’re likely to have when babies are born, but there’s a critical aspect of patient survival related to the vasculature that we as a specialty have difficulty measuring and predicting. We need a greater understanding of their challenges as they grow. The CDH Registry provides excellent information but we also rely on the physicians who see the patients long term to conduct research on outcomes and publish it.”

To that end, Matthew Harting, M.D., is creating a Congenital Diaphragmatic Hernia Clinic through UT Physicians to track children over the long haul. “We’re saving more and more of these kids but they’re living with a host of medical issues. At the clinic they’ll be able to see a team of specialists in one location, which will allow us to optimize their care, collect data and understand their challenges in ways that were previously impossible.”

Dr. Harting is also engaged in promising research using exosomes, small membrane particles released from mesenchymal stem cells, to help manage pulmonary hypertension. “Because we still have a 30 percent mortality rate, we’re trying to push the envelope in basic science and translational research to move the care of these critically ill babies to the next level,” says Dr. Harting, who is director of the pediatric ECMO program at Children’s Memorial Hermann Hospital and an assistant professor in the division of General and Thoracic Pediatric Surgery. “There is some evidence that stem cells can halt the progression of pulmonary hypertension but no evidence yet on how that effect applies to diaphragmatic hernia. This is still very early work but if we find that it’s as efficacious as we hope it will be, we can translate it to the clinical setting to mitigate some of the pulmonary hypertension we see in CDH.

“Over the last 20 years, Dr. Lally has put his heart and soul into getting physicians to collaborate internationally on this rare health issue,” Dr. Harting says. “That effort has paid off in lives saved but we also need new therapies, which is why the research we’re doing at The Fetal Center is important. We are state-of-the-art and expert at providing the full continuum of care for diaphragmatic hernia. Prenatally we can offer patients FETO, postnatally we have excellent clinical outcomes and we’re engaged in basic science research to develop new ways to take care of patients.”

¹Harrison MR, Keller RL, Hawgood SB, Kitterman JA, Sandberg PL, Farmer DL, Lee H, Filly RA, Farrell JA, Albanese CT. A Randomized Trial of Fetal Endoscopic Tracheal Occlusion for Severe Fetal Congenital Diaphragmatic Hernia. *New England Journal of Medicine*. 2003 Nov 13;349:1916-24.

²Jani JC, Nicolaidis KH, Gratacos E, Valencia CM, Done E, Martinez JM, Deprest J. Severe diaphragmatic hernia treated by fetal endoscopic tracheal occlusion. *Ultrasound in Obstetrics and Gynecology*. 2009 Sept;34(3)3:304-10.

Patient Referrals to the TOTAL Trial

Inclusion Criteria

- Consenting subjects
- Fetus with isolated left-sided congenital diaphragmatic hernia
- Severe pulmonary hypoplasia defined as O/E LHR <25 percent
- Liver up
- Willingness to live within 30 minutes of Children’s Memorial Hermann Hospital

Exclusion Criteria

- Maternal contraindication to fetal intervention
- Technical or maternal limitation to fetoscopy
- Preterm labor or cervix <15 millimeters
- Refusal to return to The Fetal Center during the time period airways are occluded

To refer a patient for evaluation for fetal endoscopic tracheal occlusion as part of the TOTAL trial, call 832.325.7288.

Patient Story



Megan Webb and her twins, Jayden (L) and Luke (R)

Jayden and Luke. Two-year-old identical twin boys. They run and wrestle, giggle and converse in their own shared lingo – jibber-jabber only they understand. But Jayden is taller, more robust. Luke wears the same size clothes as the boys' younger brother Cooper. Each of the twins in his own way is a medical miracle. Luke was born with a congenital diaphragmatic hernia (CDH). In spite of being Luke's identical twin, Jayden was not affected.

CDH, a condition that affects only about 1,000 babies born each year, occurs when a hole develops in the fetus' diaphragm, allowing abdominal organs to intrude into the chest cavity. This results in compression and underdevelopment of the lungs and abnormalities in the pulmonary blood vessels. Newborns typically suffer from breathing difficulties related to their abnormal lungs. Many infants with CDH only have problems related to the diaphragm and lungs, while others may have complications such as developmental problems with the brain, heart, kidneys and bowel. The exact cause of CDH is unknown.

Luke and Jayden's dad and mom, Ryan and Megan Webb of San Angelo, Texas, learned at 19 weeks that a sonogram had revealed an anomaly in one of the twins. Dr. Jorge Blanco, their maternal fetal medicine specialist (MFM), suspected either CDH or CCAM (congenital cystic adenomatoid malformation) and referred them to The Fetal Center at Children's Memorial Hermann Hospital.

Luke's dad, Ryan, remembers many of the milestones before the twins' birth in terms of holidays. "On the Tuesday before Thanksgiving, the sonogram showed a part of Luke's stomach reaching into his chest cavity. On the Monday after Thanksgiving, we were in Houston."

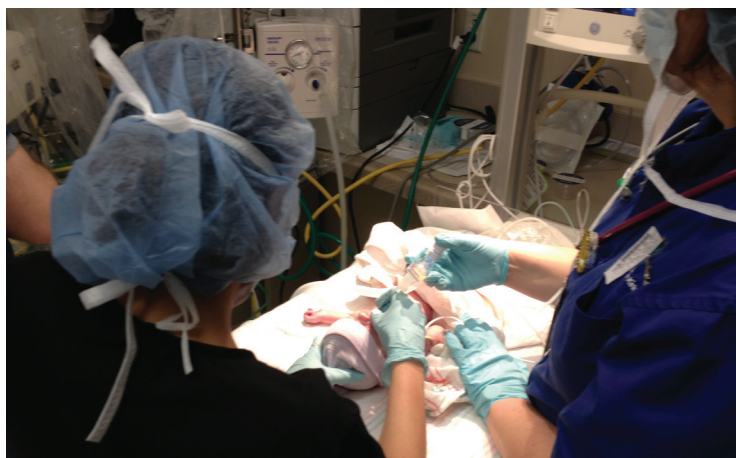That was a long day for the Webbs. Their initial meeting with The Fetal Center's co-director KuoJen Tsao, M.D., pediatric surgeon at McGovern Medical School, was followed by a two-hour sonogram, an hour-and-a-half echocardiogram and a one-hour MRI. Then consultations with a geneticist and a cardiologist and a wrap-up with Dr. Tsao, who counseled them about what to expect and explained that the severity of the problem, which would become more apparent as the pregnancy proceeded, would determine how their baby's CDH would be treated. It was, according to Ryan, an "all-day ordeal" – with more questions than answers – ending with a six-hour drive back to San Angelo.

Among the answers: The MRI confirmed CDH in one baby, but showed no other malformations. Among the questions: Was a genetic problem at the root of the CDH? Was it possible that one identical twin could be affected and not the other? Considering the wide spectrum of possible damage, what do you do to prepare for the worst while hoping for the best?

Megan's prenatal team – Dr. Blanco in San Angelo and the affiliated physicians at The Fetal Center – recommended that she return to Houston a month before her due date in case of a possible early delivery. Because Ryan works independently, he was able to join her, so in January 2014, the Webbs packed up and temporarily relocated to Houston. "I worked from the apartment," he recalls, "while my poor wife slept on the couch."

The babies were due on February 19. On the 8th – just before Valentine's Day – Megan and Ryan headed for their regular Friday appointment at The Fetal Center, which included a weekly sonogram. She remembers her physician saying, "You're going to have these babies soon." "How soon?" she asked. "Today."

Patient Story



She hadn't brought her purse with her, much less a bag packed for a stay in the hospital. That didn't matter as it was time to deliver her boys; the staff put her in a wheelchair, rolled her across the Fannin Street sky bridge and headed for Children's Memorial Hermann Hospital. The babies were delivered by C-section that evening with two full medical teams in attendance: one for Luke, the other for Jayden. Ryan remembers a room packed with specialists all focused on bringing two special boys into the world.

Jayden came out screaming – just as expected. Luke, too, came out just as expected, but this time, the parents recall, it was eerily silent. They were prepared for the fact that Luke would have complete respiratory failure when he emerged. A

nurse was standing by with a portable apparatus that would “breathe” for him until he got onto a ventilator. Megan kissed him on the forehead and he headed for the Neonatal Intensive Care Unit (NICU), where he would stay for the next 40 days.

Ryan describes Children's Memorial Hermann's NICU as “absolutely amazing.” “They took care of Luke like he was their own child,” Megan adds. “We couldn't hold him ourselves because it would overstimulate him, but the nurses knew exactly what he needed.”

They remember with special fondness one nurse who asked to take care of Luke on every one of his shifts. “During one of our follow-up visits, he was at the hospital, so we had a little reunion,” Megan recalls. “Luke never wanted to go to anyone, but he recognized that nurse. He held his arms out and went right to him.”

Before any happy reunions were possible, Luke had a long way to go on his medical journey. His condition had to stabilize and his blood oxygen levels improve before the hernia could be repaired. The repair procedure is performed seven to 14 days after birth, a delay that allows the baby's condition to stabilize. Mary Austin, M.D., a pediatric surgeon at McGovern Medical School and member of The Fetal Center team, monitored Luke's progress carefully to determine when conditions were – as Ryan describes them – “just right.” Everything came together when Luke was 11 days old. During the repair surgery, Dr. Austin performed a laparotomy, using Luke's existing tissue rather than mesh, to patch the hole in his diaphragm. The tissue allowed the repair to grow with him and minimized the need for subsequent surgery to replace an “outgrown” patch.

After the repair, Luke's lungs began to expand, paving the way for him to breathe without a ventilator. The next challenge was to deal with coarctation – narrowing – of the aorta. On March 1, a heart catheterization expanded Luke's narrowed aorta, allowing him some extra healing time before undergoing another major procedure. He started gaining weight and breathing on his own and on March 18 he left the NICU for a long-awaited reunion with his twin brother at the Webbs' home away from home.

On the day before Easter, the Webbs left for West Texas as a family – a slow trip across half the state, punctuated with frequent stops. The hours didn't matter; what Megan remembers most is putting Luke in his own crib for the first time.



Several months later, Luke underwent a follow-up surgery for the coarctation, after which he became, as his mother describes him, “an entirely different baby. He went from being fussy to happy – laughing and giggling all the time.”

Today, she describes Luke as a “walking, talking, running machine.” Both toddlers have crossed the developmental milestones that you'd expect at their age, but “Luke gets so excited when he does something before Jayden,” their mother reports.

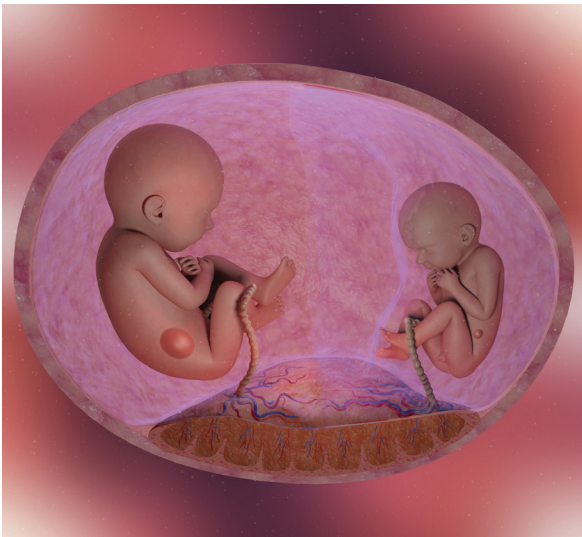
A half a state away from Houston, the Webbs speak glowingly of Children's Memorial Hermann and the love and care their family received at The Fetal Center and NICU. “There's nothing we can do to repay them for that.”

News of Note - Patient Education

Patient Education Video Series

The Fetal Center at Children's Memorial Hermann Hospital has created an online patient education video series dedicated to informing patients and their families about prenatal and postnatal care for specific fetal conditions. The video series is an educational tool for patients and their families to learn more about specific conditions and explore available treatment options, while also serving as a helpful resource to physicians who strive to best communicate clinical details so that families can make the most informed decisions possible for their loved ones.

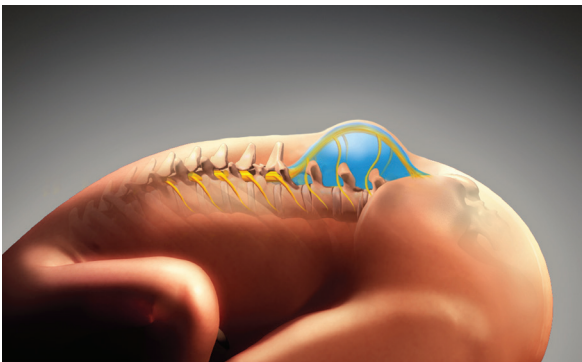
Currently, two patient education videos are featured on our website in both English and Spanish. These include:



The Twin-Twin Transfusion Syndrome Patient Education Video

This video provides families with objective clinical information about the potential risks associated with monochorionic twins as well as detailed information about the available treatment options, including laser photocoagulation for severe TTTS. An animated guide is provided to families showing the five stages of TTTS, along with information about other common conditions that may affect multifetal gestations.

To view the TTTS video, visit childrensmemorialhermann.org/ttts.



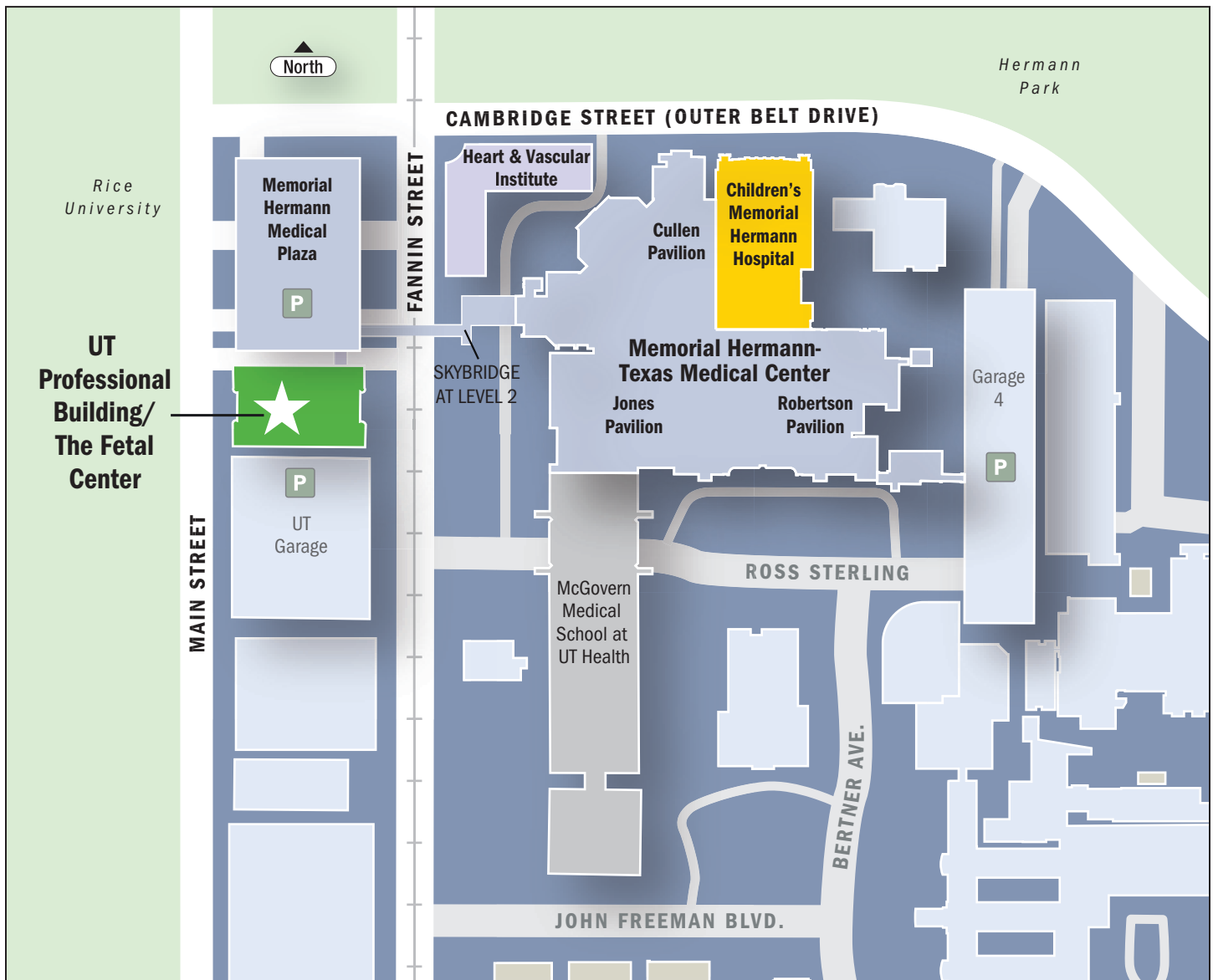
The Fetal Spina Bifida Patient Educational Video

This video provides families with comprehensive information about the etiology and natural history of spina bifida as well as the pathophysiology leading to the many complications associated with the condition. The patient education videos provide families with a step-by-step guide through the comprehensive, multidisciplinary evaluation and consultation process followed by a detailed look at the fetal surgery patient experience.

To view the Fetal Spina Bifida video in English or Spanish, visit childrensmemorialhermann.org/spina-bifida.

For more information, email thefetalcenter@memorialhermann.org or call 832.325.7288.

Contacts



Location

6410 Fannin, Suite 210
 UT Professional Building
 Houston, TX 77030

Phone: 832.325.7288
Toll free: 1.888.818.4818
Fax: 713.383.1464

Email: thefetalcenter@memorialhermann.org
Website: childrensmemorialhermann.org/thefetalcenter



[Facebook.com/TheFetalCenter](https://www.facebook.com/TheFetalCenter)



[Twitter.com/TheFetalCenter](https://twitter.com/TheFetalCenter)

DIGITAL VERSION: To opt in for a digital version of this newsletter, visit: childrens.memorialhermann.org/fetal/newsletter

Memorial Hermann Health System



7737 Southwest Freeway, Suite C-25
Houston, TX 77074-9777

childrens.memorialhermann.org

Nonprofit Org.
U.S. POSTAGE
PAID
Permit No. 3156
Houston, TX



The Fetal Center
6410 Fannin, Suite 210
Houston, TX 77030
childrensmemorialhermann.org/thefetalcenter