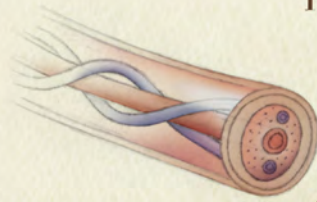


# CHILDREN'S MEMORIAL HERMANN HOSPITAL PEDIATRIC NEUROSCIENCE JOURNAL

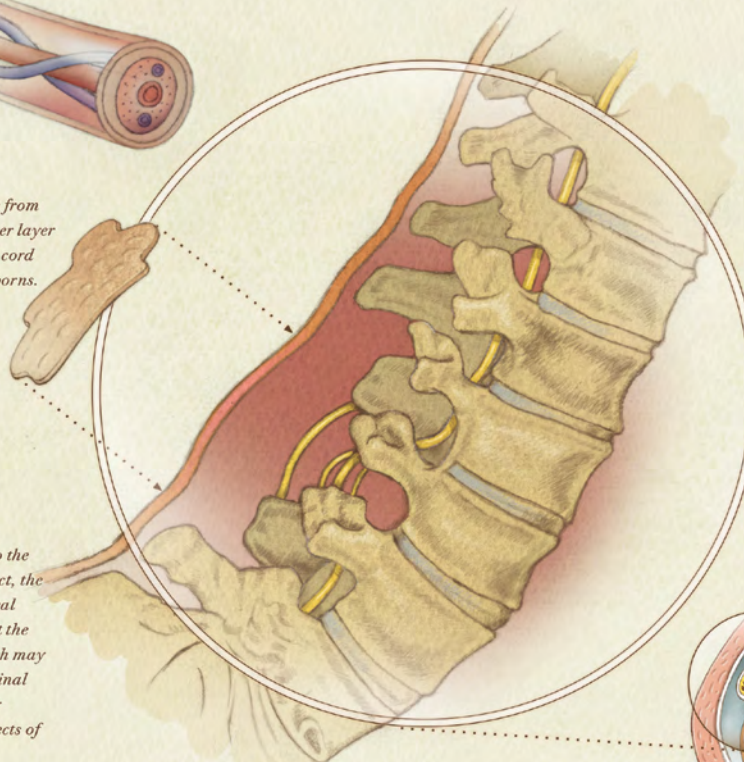
A PUBLICATION OF CHILDREN'S MEMORIAL HERMANN HOSPITAL AND MCGOVERN MEDICAL SCHOOL AT UTHEALTH

## In Utero Myelomeningocele Repair


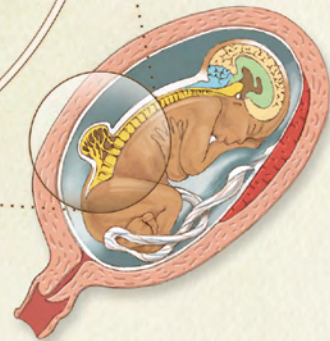


*A patch is made from the donated outer layer of the umbilical cord of healthy newborns.*

*When applied to the neural tube defect, the patch allows local tissue to grow at the repair site, which may help improve spinal cord function by reducing the effects of scar tissue.*



*For the first time, a bioscaffold has been used successfully for in utero spina bifida repair, allowing the fetus to heal itself and heralding a new era for minimally invasive myelomeningocele repair.*



# IN THIS ISSUE

---

**01** Building a Bridge from the Bench to the Bedside

## FEATURES

**02** Umbilical Cord Patch Shows Promise as Novel Method for In Utero Myelomeningocele Repair

**06** Endoscopic Treatment for Hydrocephalus: Another Infant Avoids a Shunt

**08** Robert Noack Benefits from Endoscopic Management of Sagittal Craniosynostosis

**10** Nine Minutes to the Operating Table: Saving the Life of a Child

**12** Two Memorial Hermann/UTHealth Physicians Work to Improve Epilepsy Care in Nicaragua

**14** Helping Out in Haiti: A Houston Surgical Team Travels South to Treat Children with Hydrocephalus

## RESEARCH

**16** Two Novel Studies Seek to Improve Outcomes in Children with Malignant Fourth Ventricular Brain Tumors

**17** In the Lab: Researchers Prepare to Test a Novel High-resolution Near-infrared Functional Brain Imaging System in Pediatric Patients

## NEWS OF NOTE

**18** Dr. Ian Butler Receives Regents' Outstanding Teaching Award

**19** Dr. Manish N. Shah Named a Texas Super Doctors Rising Star

Report on the 2017 Run for the Rose

**20** SELECTED PUBLICATIONS

# BUILDING *a* BRIDGE *from the* BENCH *to the* BEDSIDE

Taking an idea from the lab to clinical use typically takes about a decade. Thanks to strong collaborators with a track record of success in their fields, we're doing it much faster.

Based on a seven-year foundation of research in animal models, it took a team of surgeons at The Fetal Center just two and a half years to move a new patch that holds promise for treating spina bifida in utero from the lab to the bedside – our cover story for this issue. For the first time a bioscaffold – a patch made from the donated outer layer of the umbilical cord of healthy newborns – has been successfully employed to allow a fetus diagnosed with myelomeningocele to heal itself. Conducted at Children's Memorial Hermann Hospital and McGovern Medical School at UTHealth and led by maternal-fetal medicine specialist Ramesha Papanna, M.D., M.P.H., and pediatric neurosurgeon Stephen Fletcher, D.O., the study made the cover of *Obstetrics & Gynecology* last July.

At the Brown Foundation Institute of Molecular Medicine (IMM) for the Prevention of Human Diseases, Eva Sevick, Ph.D., Banghe Zhu, Ph.D., and Manish N. Shah, M.D., are using military-based technology to develop a high-resolution near-infrared imaging platform with the capability to acquire hundreds of measurements simultaneously from the brains of infants and children – without ionizing radiation or the need for sedation. The novel method uses functional near-infrared spectroscopy and diffuse optical tomography (fNIRS-DOT), a combination that may one day change the way physicians manage children with spasticity, epilepsy and other neurological disorders.

Clinicians and investigators have been pioneers in developing new treatments for children with malignant brain tumors. This issue highlights two novel clinical trials, both recently approved by the Food and Drug Administration (FDA), that are being performed at our center. One investigates the safety and efficacy of combination methotrexate and etoposide infusions into the fourth ventricle in children with recurrent posterior fossa brain tumors. In the other, we hope to establish the safety and efficacy of direct administration of 5-azacytidine into the fourth ventricle in children with recurrent posterior fossa ependymoma.

In addition to conducting cutting-edge neuroscience research, we continue to push the envelope to offer the least invasive and most timely neurosurgical procedures to our young patients. We're grateful to Kendall Lowery for sharing the story of her daughter, Harper, who underwent endoscopic management of her hydrocephalus and avoided a shunt. We'd also like to thank Heather Hicks for sharing the story of her son Robert Noack, who underwent endoscopic repair of sagittal craniosynostosis, and Ellie and Stephen Courtney of Lufkin, Texas, whose son, Landon, was airlifted to Houston for emergency surgery for a large epidural hematoma.

We hope you find the articles in this issue of the *Pediatric Neuroscience Journal* interesting and useful. If you have questions about any of our programs, please feel free to contact us directly.

With best wishes,



**DAVID I. SANDBERG, M.D., FAANS, FACS, FAAP**

Professor and Director of Pediatric Neurosurgery  
Dr. Mamie Rose Professorship in Pediatric Neurosurgery  
Department of Pediatric Surgery and Vivian L. Smith Department of Neurosurgery  
McGovern Medical School at UTHealth, Children's Memorial Hermann Hospital and Memorial  
Hermann Mischer Neuroscience Institute at the Texas Medical Center

Co-Director, Pediatric Brain Tumor Program  
The University of Texas MD Anderson Cancer Center  
713.500.7370



**IAN J. BUTLER, M.D.**

Professor and Director of Child and Adolescent Neurology  
Distinguished Chair in West Syndrome Research  
McGovern Medical School at UTHealth  
713.500.7142

# UMBILICAL CORD PATCH SHOWS PROMISE *as* NOVEL METHOD *for* IN UTERO MYELOMENINGOCELE REPAIR

A patch made from cryopreserved human umbilical cord may prove to be a novel method for treating myelomeningocele in utero, according to researchers at McGovern Medical School at UTHealth. The findings were published in July 2016 in *Obstetrics & Gynecology*,<sup>1</sup> the journal of the American Congress of Obstetricians and Gynecologists.

**“WITHIN TWO WEEKS, THE SKIN HAD HEALED OVER THE PATCH SPONTANEOUSLY. THE CHILD HAD NORMAL MOVEMENTS OF THE LOWER EXTREMITIES AND BLADDER CONTROL FUNCTION, AND THERE WAS A COMPLETE REVERSAL OF THE CHIARI II MALFORMATION.”**

Made of the donated outer layer of the umbilical cord of healthy newborns, the patch was used for repairs performed at Children’s Memorial Hermann Hospital. “The umbilical cord contains a specific natural material called heavy chain hyaluronic acid/pentraxin3, which has regenerative properties,” says lead author Ramesha Papanna, M.D., M.P.H., an assistant professor in the department of Obstetrics, Gynecology and Reproductive Sciences at McGovern Medical School and maternal-fetal medicine specialist at The Fetal Center at Children’s Memorial Hermann Hospital. “It allows the local tissue to grow in at the repair site instead of healing by scar formation, which occurs with traditional repair methods. This decrease in scar formation may help improve the spinal cord function further and reduce the need for future surgeries to remove the effects of the scar tissue on the spinal cord.”



**RAMESHA PAPANNA, M.D., M.P.H.**  
Assistant Professor, Department of Obstetrics,  
Gynecology and Reproductive Sciences  
McGovern Medical School at UTHealth

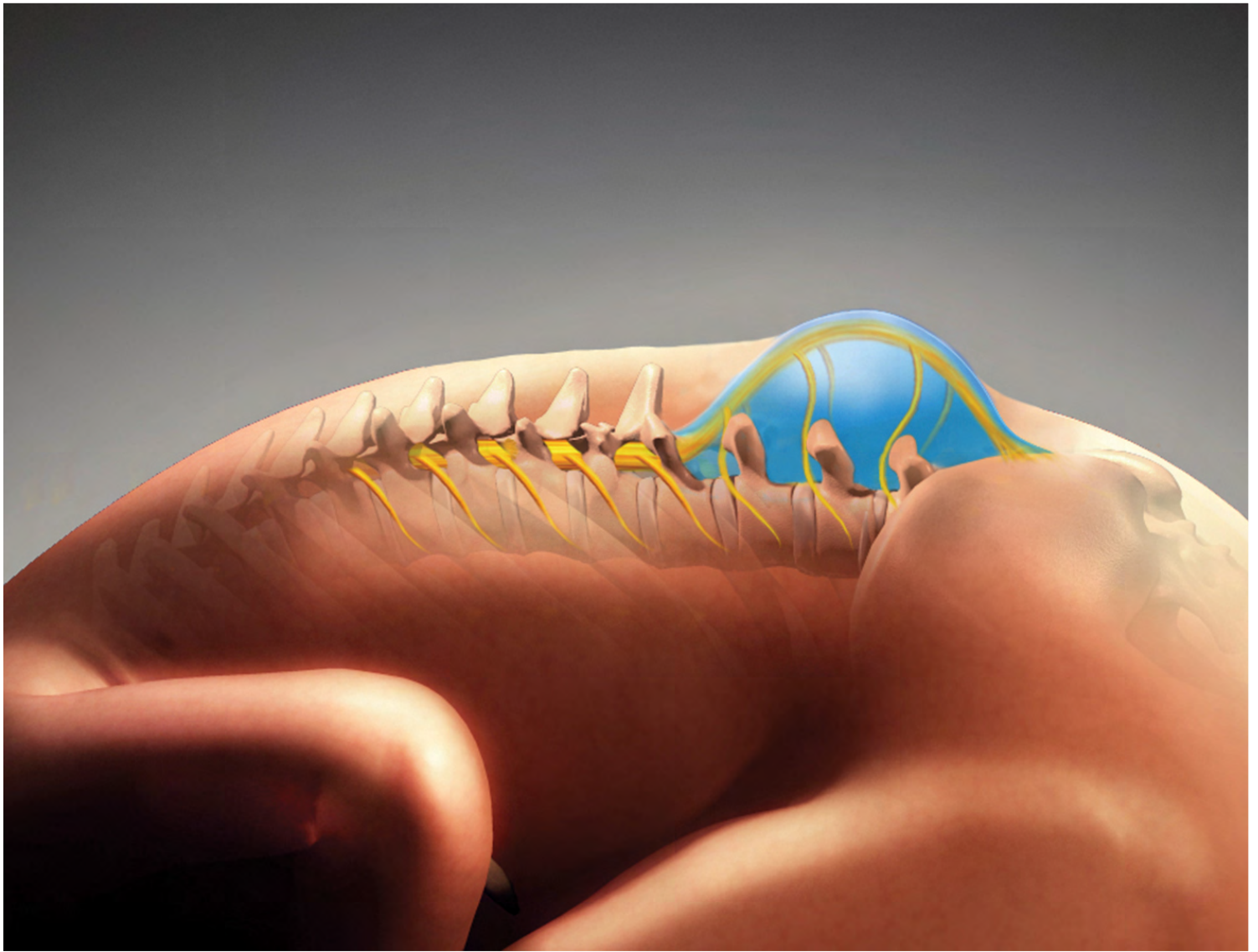According to the National Institute of Neurological Disorders and Stroke, myelomeningocele – characterized by the incomplete development of the coverings of the brain, spinal cord or meninges – is the most common neural tube defect in the United States, affecting 1,500 to 2,000 of the more than 4 million babies born each year. The defect can result in paralysis, urinary or bowel dysfunction, and mental retardation.

In 2011, a landmark clinical trial – the Management of Myelomeningocele Study (MOMS) sponsored by the National Institutes of Health – found that if a fetus underwent in utero surgery to close the defect, the serious complications associated with spina bifida could be lessened or even reversed. In cases where the defect was too large to close with the fetus’ existing skin, a patch was necessary. But in some cases, scar tissue may cause adherence of the patch to the underlying spinal cord, which could result in a loss of neurologic function as the child ages. Further surgery is often needed to remove the scar tissue.

“The use of this patch for fetal repair heralds a new era for fetal spina bifida repair,” says Kenneth Moise, M.D., co-author, professor and co-director of The Fetal Center at Children’s Memorial Hermann Hospital and McGovern Medical School. “For the first time, a bioscaffold has been successfully employed to allow the fetus to heal itself. The implications for the future of a minimally invasive approach to fetal spina bifida repair and even neonatal spina bifida repair are enormous.”



**KENNETH MOISE, M.D.**  
Co-Director, The Fetal Center  
Professor, Department of Obstetrics,  
Gynecology and Reproductive Sciences  
McGovern Medical School at UTHealth



In the first case study, the skin lesion in the fetus measured 5 centimeters by 6 centimeters and there was evidence of Chiari II malformation, a complication of spina bifida in which the brain stem and the cerebellum protrude into the spinal canal or neck area. Chiari II can lead to problems with feeding, swallowing or breathing control.

At 24 weeks gestation, the patient underwent fetal surgery performed by Stephen Fletcher, D.O., co-author, associate professor in McGovern Medical School's Department of Pediatric Surgery and a pediatric neurosurgeon affiliated with Memorial Hermann Mischer Neuroscience Institute and Children's Memorial Hermann Hospital, and KuoJen Tsao, M.D., associate professor and The Children's Fund Distinguished

Professor in Pediatric Surgery and co-director of The Fetal Center. Dr. Moise and Dr. Papanna also participated in the surgery.



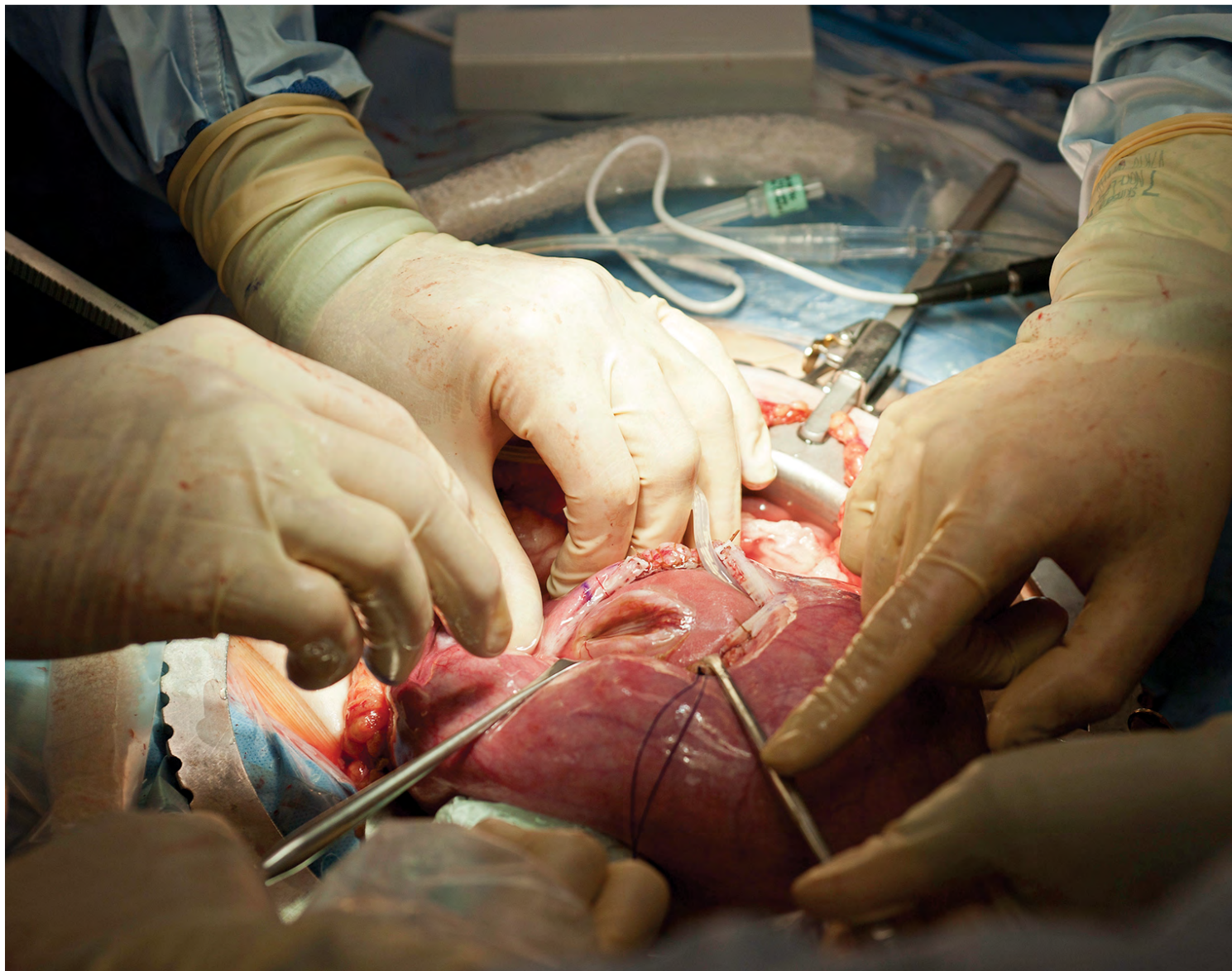
**STEPHEN FLETCHER, D.O.**  
*Associate Professor, Division of Pediatric Neurosurgery  
McGovern Medical School at UTHealth*



**KUOJEN TSAO, M.D.**  
*Co-Director, The Fetal Center  
Professor, Department of Pediatric Surgery  
McGovern Medical School at UTHealth*

“The lesion was closed with skin edges sutured to the human umbilical cord patch in a watertight fashion, and the mother was discharged on postoperative day 5,” Dr. Fletcher says. “The baby

**For the first time a bioscaffold has been successfully employed to allow the fetus with myelomeningocele to heal itself.**



**The lesion was closed with skin edges sutured to the human umbilical cord patch in a watertight fashion. The skin grew over the patch and by day 30 was completely healed.**

was born at 37.5 weeks and the patch was intact with no leakage of fluid. At the site of the lesion it appeared semi-translucent with incomplete regeneration of the skin, but within two weeks, the skin had healed over the patch spontaneously. The child had normal movements of the lower extremities and bladder control function, and there was a complete reversal of the Chiari II malformation.”

In the second case, performed by the same team, the patient’s fetus had a lesion of 4 centimeters by 5 centimeters and Chiari II malformation. The expectant mother underwent surgery at 25 weeks gestation, and the procedure and application of the patch were similar to the first case. The baby was delivered at 37.5 weeks with complete covering of the

lesion with the patch but without skin grown into the patch. As with the first case, the skin grew over the patch and by day 30 was completely healed. There was normal motor and urinary function and the Chiari II malformation was completely reversed.

Both cases were approved by the U.S. Food and Drug Administration under Expanded Access use, by the Fetal Therapy Board of The Fetal Center at Children’s Memorial Hermann Hospital and by the UTHealth Institutional Review Board prior to the surgery.

The clinical cases were the culmination of seven years of research after Dr. Papanna and co-author Lovepreet K. Mann, M.B.B.S., an instructor in McGovern Medical School’s Department of

Obstetrics, Gynecology and Reproductive Sciences, began brainstorming ideas about possible patch materials. Their research led them to their co-author Scheffer C.G. Tseng, M.D., Ph.D., of Ocular Surface Center and TissueTech, Inc., in Miami, Fla., who was using human amniotic membrane and umbilical cord – donated by mothers of healthy infants – to repair corneas. The patch is approved by the FDA for corneal repair.

“This patch acts as a scaffold, which is watertight and allows native tissue to regenerate in an organized manner, and also has anti-scarring, anti-inflammatory properties,” Mann says. “Preventing the scarring could prevent tethering, which can in turn prevent further damage to the cord.”

The patch was first tested in animal models by a team of researchers that included Dr. Papanna, Dr. Fletcher, Dr. Mann, Dr. Moise and Saul Snowise, M.D., a maternal-fetal fellow who has since joined McGovern Medical School as an assistant professor in the department of Obstetrics, Gynecology and Reproductive Sciences.

In 2011, after the national MOMS trial for fetal surgery was ended early because of positive results, physicians at McGovern Medical School and The Fetal Center were the first in Texas to perform the newly approved surgery. Since then, the team has performed more than 40 fetal surgeries to treat spina bifida.

Dr. Mann said the team was taken aback at first by the lack of skin covering the patch at the birth of the first infant, but she could see the child’s legs moving and recognized it was an early success that they hope will continue as the baby grows. “If we can make a small change and improve the quality of life for the child, that will mean we really accomplished something.”

The team has since completed two additional surgeries using the patch, and Dr. Fletcher has used the new patch in surgeries to untether the spinal cord of children who had previous spina bifida

surgery. Discussions are ongoing with the FDA for an IDE application to allow for a clinical trial based on the pilot results from the first four patients.

Currently, the team members are working on finding ways to make the skin heal inside the uterus and different ways to deploy the patch over the defect site through less-invasive means. “We’ve made progress at an incredibly rapid pace,” Dr. Papanna says. “Taking an idea from the lab to human use typically takes about a decade. We’ve been able to reduce that time to two and a half years. We have a good system in place with strong collaborators, all of whom have a track record of success in their fields.”

---

**“WHAT WE’VE DONE TO DATE IN SHOWING REAL BENEFIT TO CHILDREN IS JUST THE TIP OF THE ICEBERG. WE WANT ALL BABIES WHO UNDERGO THE FETAL SURGERY TO BE ABLE TO WALK AT AGE 3.”**

---

Research collaborators from other institutions and disciplines across the country include Sanjay Prabhu, M.B.B.S., assistant professor of pediatric neuro-radiology at Harvard Medical School; Raymond Grill, Ph.D., associate professor of neurobiology and anatomical sciences at the University of Mississippi; and Russell Stewart, Ph.D., professor of biomedical engineering at the University of Utah.

“Children’s Memorial Hermann Hospital is about patients. If they’re not here, we’re not here,” Dr. Papanna says. “There’s still plenty of work to do. What we’ve done to date in showing real benefit to children is just the tip of the iceberg. We want all babies who undergo the fetal surgery to be able to walk at age 3. Right now, the percentage is less than half. Our goal is to take it to 100 percent.”

---

<sup>1</sup> Papanna R, Fletcher S, Moise KJ Jr, Mann LK, Tseng SC. Cryopreserved Human Umbilical Cord for In Utero Myelomeningocele Repair. *Obstet Gynecol.* 2016 Aug;128(2):325-30.

# ENDOSCOPIC TREATMENT *for* HYDROCEPHALUS: ANOTHER INFANT AVOIDS *a* SHUNT

**H**arper Lowery was born prematurely at 29 weeks 6 days, the larger of fraternal twins. A cranial ultrasound performed at 10 days of life revealed a bilateral intraventricular hemorrhage. With blood clots blocking the flow of cerebrospinal fluid (CSF), Harper's head began to enlarge to accommodate the buildup, an indication of hydrocephalus. Spinal taps relieved some of the pressure on the ventricles, and on Christmas Eve of 2012, she was transferred to Children's Memorial Hermann Hospital, where pediatric neurosurgeon Stephen Fletcher, D.O., implanted an Ommaya reservoir for aspiration of CSF as a temporizing solution.

**“THE BEST WAY TO AVOID SHUNT COMPLICATIONS IS TO AVOID PLACING A SHUNT WHENEVER POSSIBLE, AND THAT IS EXACTLY WHAT WE TRY TO DO BY OFFERING ENDOSCOPIC PROCEDURES.”**

“We were hoping the ventricular taps would buy her some time to grow,” says Harper's mother, Kendall Lowery. “After we learned she had hydrocephalus, we did our research and decided on an endoscopic third ventriculostomy rather than the traditional surgery to place a shunt. We believe strongly in taking advantage of any cutting-edge medical procedure to help our child.”

In late January 2013, when Harper was a month and a half old, pediatric neurosurgeon David Sandberg, M.D., FAANS, FACS, FAAP, performed an endoscopic third ventriculostomy and choroid plexus cauterization (ETV-CPC). Using a neuroendoscope with fiberoptic technology to visualize small and difficult-to-reach

surgical areas, Dr. Sandberg created an opening in the floor of the third ventricle, allowing the CSF to bypass the obstruction and flow around the surface of the brain for resorption. He also performed a septostomy, allowing the two sides of the brain to communicate. In addition, he cauterized the choroid plexus, which produces most of the CSF in the brain, in order to reduce CSF production.



**DAVID SANDBERG, M.D., FAANS, FACS, FAAP**  
*Director, Pediatric Neurosurgery; Professor and Chief, Division of Pediatric Neurosurgery; Dr. Marnie Rose Professorship in Pediatric Neurosurgery*  
McGovern Medical School at UTHealth

“At most centers, most infants would have received a shunt,” says Dr. Sandberg, who holds the Dr. Marnie Rose Professorship in Pediatric Neurosurgery at McGovern Medical School at UTHealth and is director of pediatric neurosurgery at Children's Memorial Hermann Hospital, Mischer Neuroscience Institute and the medical school. “While shunts are simple to place, they frequently malfunction. Within the first year of placement there's a 30 percent to 45 percent failure rate and a 4 percent failure rate every year afterwards for the rest of the child's life. As a result, some children with shunts require numerous surgeries throughout their childhood. Shunts also have a higher infection rate than endoscopic procedures. The best way to avoid shunt complications is to avoid placing a shunt whenever possible, and that is exactly what we try to do by offering endoscopic procedures.”

Harper bounced back quickly and came home in early February after a two-month NICU stay. “We were told that the soft spot on her head would bulge as a first indicator of failure of the ETV procedure, so for the first year of her life, I felt her head probably 100 times a day,” Lowery admits. “We did routine MRIs, and she progressed well. The nice thing about having twins is that her brother, Landon, gave us a good marker for Harper's development.”



Four years have passed since the surgery, and Harper has not required any additional surgeries for hydrocephalus. Her parents are very pleased with the result of the endoscopic procedure and how the rationale for it was explained to them.

“It is so vital for parents to be really involved in the care of their children,” Kendall Lowery says. “Not one thing was done that I didn’t ask questions about and made sure I understood. And Dr. Sandberg explained everything to us. He’s the most amazing doctor I’ve known in my life – a great surgeon and a great, great person.”

Hydrocephalus is not uncommon; some estimates report that 1 to 2 of every 1,000 infants are born with the disorder. Since Harper’s surgery, Lowery has gotten to

know two other families who have kids with hydrocephalus. “I’ve advised them not to shy away from the ETV procedure just because there is not a 100 percent guarantee of success,” she says. “You definitely want the best surgeons, which we had, but you’ve also got to have a lot of faith. If you can give your child a chance to live without a shunt, do it. I go to bed every night thankful that we made that choice.”

Harper turned four last December. “She’s developing well and doing beautifully,” says Dr. Sandberg, who sees her annually in follow-up. “It’s such a thrill to watch her talking normally and running around the office. Physicians at many centers are reluctant to do endoscopic neurosurgery on babies. We can offer that benefit. When the procedure works, it’s a home run for kids and their families.”

---

**Four years have passed since Harper Lowery underwent an endoscopic third ventriculostomy. Today she lives a normal life without a shunt.**



# ROBERT NOACK BENEFITS *from* ENDOSCOPIC MANAGEMENT *of* SAGITTAL CRANIOSYNOSTOSIS

**H**eather Hicks noticed the odd shape of her son Robert Noack's head as soon as he was born. "His head was long and narrow, shaped kind of like a peanut," she says. "At the time I was the only one who was concerned."

Hicks and her family are residents of Willis, Texas, a small community about an hour north of Houston. In a fortunate twist of fate, Robert contracted respiratory syncytial virus at the age of two weeks, and was admitted to a downtown hospital where he was in intensive care for nearly a month. "I was still super concerned about the shape of his head, and finally one of his doctors recognized that he had craniosynostosis."

---

**"THE TEXAS CLEFT-CRANIOFACIAL TEAM HAS ONE OF THE LONGEST HISTORIES MANAGING CRANIOSYNOSTOSIS, AND THE ADDITION OF THE NEWER ENDOSCOPIC TECHNIQUE KEEPS OUR INSTITUTION ON THE CUTTING EDGE OF TREATMENT."**

---

The physician referred her to pediatric neurosurgeon Manish N. Shah, M.D., and pediatric plastic and craniofacial surgeon Matthew Greives, M.D., who work together as part of the renowned Texas Cleft-Craniofacial Team at Children's Memorial Hermann Hospital and McGovern Medical School at UTHealth. Both hold faculty positions in the medical school's department of Pediatric Surgery - Dr. Shah in the division of Pediatric Neurosurgery and Dr. Greives in the division of Pediatric Plastic and Craniofacial Surgery. The two surgeons have a track record of success collaborating on craniosynostosis cases.



**MANISH N. SHAH, M.D.**

*Director, Pediatric Spasticity and Epilepsy Surgery  
Assistant Professor, Division of Pediatric Neurosurgery  
McGovern Medical School at UTHealth*



**MATTHEW GREIVES, M.D.**

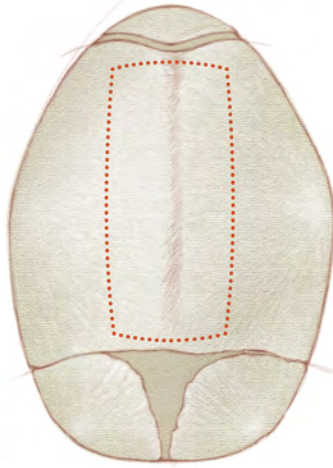
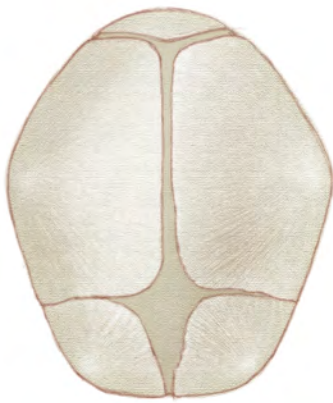
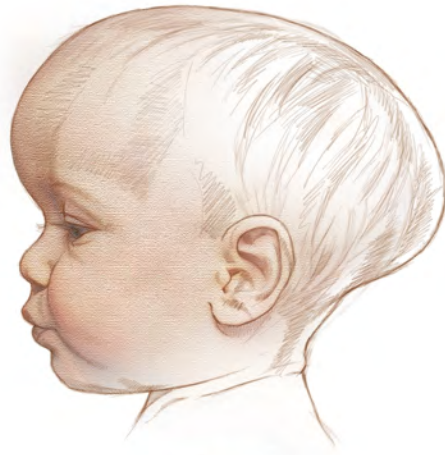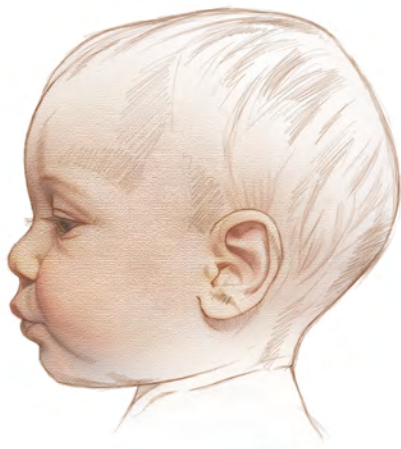*Assistant Professor, Department of Pediatric Surgery  
McGovern Medical School at UTHealth*

A rare condition that occurs in 1 in 2,500 babies born in the United States, craniosynostosis changes the growth pattern of the skull by premature fusion of its fibrous sutures. Robert is among the 40 percent to 60 percent of cases in which the sagittal suture fuses earlier than normal. Thanks to his mother's persistence and a physician's awareness of the signs of craniosynostosis, he was diagnosed well before the age of three months, early enough to qualify for endoscopic surgery.

"When certain types of craniosynostosis are diagnosed early, we can make small incisions at the front and back of the skull, visualize the fused sutures using the endoscope and remove a strip of skull bone to reopen the space between the skull plates," Dr. Shah says. "The procedure takes about 20 minutes, which means the child spends less time under anesthesia, with less bleeding and swelling than with open surgery. Most kids spend one night in the hospital."

The traditional open surgery is done on infants older than five months. A large incision is made over the top of the head, from just above one ear to just above the other. After loosening the tissue covering the bone and exposing the skull, the surgeons remove a strip of bone where the affected sutures connect. In some cases, larger pieces of bone also must be removed, reshaped and replaced. The open surgery can take from three to six hours, and most children who undergo the procedure require a blood transfusion.

Robert had the less-invasive endoscopic surgery between three and four months of age, when his skull was still pliable. No



NORMAL

SAGITTAL CRANIOSYNOSTOSIS

The illustration on the left shows a normal head shape and suture. On the right, a child with sagittal synostosis has an elongated head from front to back. The illustration at the bottom right shows a fused sagittal suture, which restricts side-to-side growth. Sagittal synostosis narrows the head from side to side, elongating the skull from front to back and resulting in the characteristic scaphocephaly shape.

transfusion was necessary. Although the endoscopic procedure has an overall 5 percent transfusion rate, to date, Dr. Shah and Dr. Greives have a 0 percent transfusion rate for all cases. When Robert's hair grew back, his scars were unnoticeable.

"The Texas Cleft-Craniofacial Team has one of the longest histories treating craniosynostosis, and the addition of the newer endoscopic technique keeps our institution on the cutting edge," Dr. Greives says. "We work closely with the helmet therapist to reduce the length of time the child spends in the helmet. They do laser scans before, during and after helmeting to follow the child's progress, and we work with them to make adjustments as necessary. We try to make it as easy on parents as possible, and those who have gone through the process with us have done well."

Dr. Shah emphasizes the importance of early diagnosis of craniosynostosis. "Our endoscopic technique is excellent but can only be done if parents and pediatricians recognize the condition early," he says. "If a child is past four months of age, the bone is too thick to use the endoscope."

Robert wore two different helmets over a period of six months to help reshape his head, the first one painted to look like a leather aviator hat complete with goggles.

"I'm so glad I kept after it and finally found doctors who could help," Heather Hicks says. "As a mom, I worry about everything that happens to my children. To avoid having us drive to Houston, Dr. Greives offered to answer any questions I had by email. I sent photos, and he responded back within an hour. They both did an amazing job."

# NINE MINUTES *to* the OPERATING TABLE: SAVING *the* LIFE of a CHILD

A small bump on the head during a game at his elementary school in Lufkin, Texas - at first Landon Courtney's injury seemed minor. The seven-year-old was playing four corners in his P.E. class in early March 2016 when his feet got tangled with a classmate's. He fell to the gym floor fast, striking his head. When the classmate and a coach helped Landon to his feet, he seemed shaken and a bit unsteady, but otherwise fine.

**“HAD LONDON ARRIVED AT THE HOSPITAL EVEN AN HOUR LATER, OR IF THERE HAD BEEN A DELAY IN GETTING HIM TO THE OR, THE OUTCOME MIGHT HAVE BEEN DIFFERENT. INSTEAD HE WALKED OUT OF THE HOSPITAL AND IS DOING FINE - THE MOST GRATIFYING EXPERIENCE FOR A PEDIATRIC NEUROSURGEON. EVEN THOUGH WE DO THIS DAY IN AND DAY OUT, I'M ALWAYS IMPRESSED BY OUR TEAMWORK AND SPEED.”**

The school nurse made a precautionary call to his mother, Ellie Courtney, who left work to check on her son. Then in a moment, everything changed. Landon began projectile vomiting and slipping in and out of consciousness. The nurse called Landon's father, this time with panic in her voice. Mrs. Courtney arrived seconds later.

“The nurse looked at me and said he needs to go to the hospital now,” she recalls. “She sat in the back with Landon, asking him questions to keep him awake, while I drove the two miles to the ER.”

Stephen Courtney arrived at the hospital a few minutes later. “Despite the turn for the worse, Landon still seemed to be okay,” he says. “The doctor evaluated him, and we initially thought it was just a really bad concussion.”

Emergency staff took Landon to the back for a CT scan. “Once we were back in the exam room, the doctor immediately came in, and his look had changed,” he says.

The couple learned that the injury had caused a large epidural hematoma that required immediate neurosurgery. The closest hospital staffed to perform the procedure was 120 miles away in Houston.

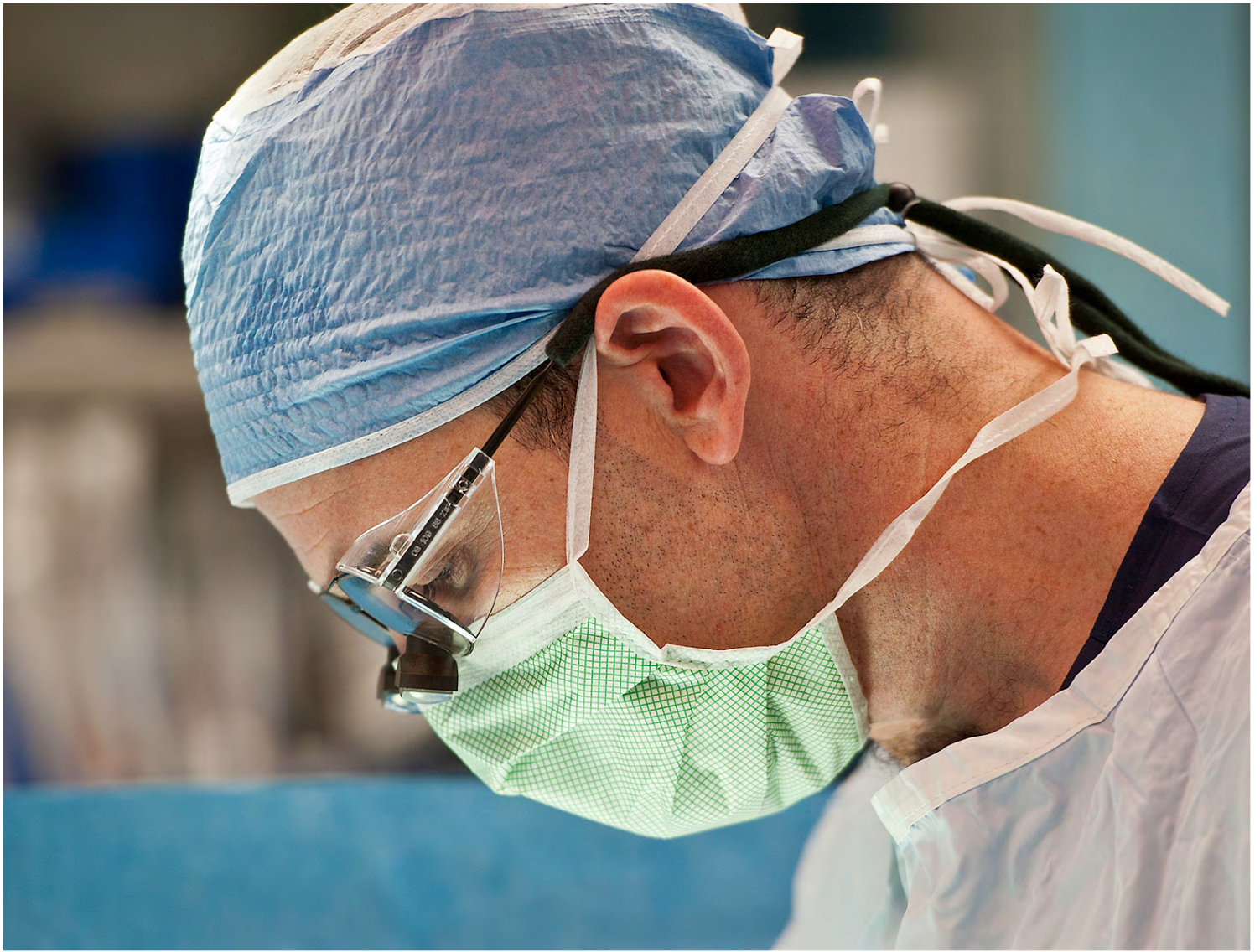David Sandberg, M.D., FAANS, FACS, FAAP, director of pediatric neurosurgery at Children's Memorial Hermann Hospital, Mischer Neuroscience Institute and McGovern Medical School at UTHealth, had just finished seeing patients in clinic when he got the call from the team at the Memorial Hermann Red Duke Trauma Institute: a seven-year-old boy in critical condition was en route to the hospital. Dr. Sandberg was at the Level 1 pediatric trauma center when Landon arrived by air ambulance.



**DAVID SANDBERG, M.D., FAANS, FACS, FAAP**  
Director, Pediatric Neurosurgery; Professor and Chief, Division of Pediatric Neurosurgery; Dr. Marnie Rose Professorship in Pediatric Neurosurgery  
McGovern Medical School at UTHealth

“As soon as I looked at him, one of his pupils started to dilate, indicating he was at risk of death without immediate surgical intervention,” says Dr. Sandberg, who holds the Dr. Marnie Rose Professorship in Pediatric Neurosurgery at UTHealth. “We had to move quickly, which we do as well as or better than any hospital in the country. As a busy pediatric trauma center we're experienced, with the knowledge and a common sense of purpose that allows us to respond fast without sacrificing safety.”

While the OR was being prepared, Dr. Sandberg called the Courtneys to explain the procedure, its risks and potential outcomes. “We were almost to Humble when he called,” says Mrs. Courtney, who is the early childhood director at Timber Creek Church in Lufkin, where her husband is the pastor.



“He said he needed to operate right away. He couldn’t promise us what the outcome would be. But he was going to do everything he could to get the blood off Landon’s brain quickly. And he asked us for our permission to operate.”

“It was so scary to hear, but we appreciated his honesty,” Pastor Courtney adds. “As we were rushing from Lufkin to Houston, we were praying and crying. And I was reminded as a father that the Lord gives us children to raise, take care of and love, but at that moment I couldn’t do any of that. All I could do was pray for my son.”

Within nine minutes of his arrival at the hospital, Landon was on the operating table with Dr. Sandberg at his side. He performed a craniotomy and saw the clot immediately. “Traumatic brain injuries

like Landon’s are not uncommon, and the surgery was straightforward - remove the clot, stop the bleeding, close the skull,” he says. “Speed is the critical factor. It’s well published that every minute counts with a brain injury. Had Landon arrived at the hospital even an hour later, or if there had been a delay in getting him to the OR, the outcome might have been different. Instead he walked out of the hospital and is doing fine - the most gratifying experience for a pediatric neurosurgeon. Even though we do this day in and day out, I’m always impressed by our teamwork and speed.”

Less than an hour after the Courtneys arrived at Children’s Memorial Hermann Hospital, Dr. Sandberg met with them to share the good news. Landon bounced back quickly after the surgery.

**“The surgery was straightforward - remove the clot, stop the bleeding, close the skull. Speed is the critical factor,” says David Sandberg, M.D., shown here in surgery.**

“Within hours of the operation he was able to smile and say, ‘Daddy.’ That’s when I lost it,” Pastor Courtney says.

A few days later, Landon was up and around, and in less than a week, he was discharged to home. Within three months, he had completely recovered and was back on his trampoline.

“When I remember the child I saw at the emergency center in Lufkin and see him today, I almost can’t believe it,” Landon’s father says. “We’re forever grateful to Dr. Sandberg and his team for saving our son’s life.”

# TWO MEMORIAL HERMANN/ UTHEALTH PHYSICIANS WORK to IMPROVE EPILEPSY CARE *in* NICARAGUA

**A**s a young physician barely into residency, Michael Funke, M.D., Ph.D., spent a year working at the Hospital Alemán-Nicaragüense (HAN) in Managua, the only public hospital on the capital city's east side, a poor and highly populated neighborhood. For the past 28 years, he has maintained a connection with the hospital and with Nicaraguan friends who finished their residencies and remained in Managua. Now, he and Gretchen Von Allmen, M.D., chief of pediatric epilepsy at Children's Memorial Hermann Hospital and director of the pediatric epilepsy program at McGovern Medical School at UTHealth, are collaborating with the Universidad de Managua to bring modern pediatric epilepsy care to the city.

**"WE HAVE A DOUBLE AIM - TO HELP THE PEOPLE OF NICARAGUA IMPROVE THE CARE THEY PROVIDE TO CHILDREN WITH EPILEPSY BY TRAINING THEIR RESIDENTS, AND TO OFFER UTHEALTH RESIDENTS AN OPPORTUNITY TO LEARN ABOUT EPILEPSY CARE IN NICARAGUA. OUR LONG-TERM GOAL IS TO HELP THE NICARAGUANS START A PEDIATRIC EPILEPSY TREATMENT PROGRAM THAT THEY CAN EVENTUALLY RUN THEMSELVES."**

"Nicaragua is one of many, many countries in the world with a health system with limited resources," says Dr. Funke, medical director of Memorial Hermann Magnetic Source Imaging and an associate professor in the division of Child and Adolescent Neurology in the department of Pediatrics at McGovern Medical School. "The Hospital Alemán-Nicaragüense



**MICHAEL FUNKE, M.D., Ph.D.**

*Medical Director, Memorial Hermann Magnetic Source Imaging  
Associate Professor, Division of Pediatric Neurology  
McGovern Medical School at UTHealth*



**GRETCHEN VON ALLMEN, M.D.**

*Director, Pediatric Epilepsy Program; Medical Director, Memorial Hermann Pediatric Epilepsy Monitoring Unit; Associate Professor, Division of Pediatric Neurology  
McGovern Medical School at UTHealth*

is part of the public health system, on which most of the population depends. There are only two EEGs in the system for children, and there is no EEG at all in the HAN, which has a service area of 700,000 people. There's a wait to schedule diagnostic studies with the single MRI they have, an open MRI system with 0.8 Tesla field strength, designed for the whole body and not ideal for brain studies for epilepsy. There are only two pediatric neurologists at La Mascota, the country's tertiary-care children's hospital, and no pediatric epileptologists in the country. We're hoping to accomplish what the World Health Organization recommends for developing countries: teach the primary care providers - in this case the pediatricians - to diagnose and treat epilepsy.

After Haiti, Nicaragua is the poorest country in Latin America. Its colonial past, history of military dictatorship, years of war and natural catastrophes have led to poverty for a large part of the population. Despite these obstacles, there are general hospitals like the HAN, which provides the basic medical specialties - internal medicine, obstetrics and gynecology, surgery and pediatrics - and specialty hospitals for other disciplines, including neurology and neurosurgery, orthopedics and cardiology.

In May 2016, after more than a year of planning, Dr. Funke and Dr. Von Allmen made their first visit to Managua, where they met with physician leaders at the university and local hospitals to begin planning for the development of a collaborative training program with UTHealth.

“We have a double aim – to help the people of Nicaragua improve the care they provide to children with epilepsy by training their residents, and to offer UTHHealth residents an opportunity to learn about epilepsy care in Nicaragua,” Dr. Von Allmen says. “Our long-term goal is to help the Nicaraguans start a pediatric epilepsy treatment program that they can eventually run themselves.”

The two physicians made a second visit in October 2016, during which they assessed and treated 25 children over a four-day period. They returned in February 2017 to continue talks about resident education programs and community outreach, and to see patients in follow-up with Nicaraguan residents and attending physicians.

Of the more than 6 million inhabitants of Nicaragua, 1 in 26 will develop epilepsy in his or her lifetime, a statistic based on prevalence in the United States. “That adds up to 250,000 people with epilepsy, about a third of whom are children,” Dr. Von Allmen says. “There is no surgery for epilepsy available in Nicaragua, which means that the patients who do have

access to treatment receive medication. One-third of children with epilepsy do not respond to medications taken on a daily basis to prevent seizures. Once a child fails two or three different anti-seizure medications with the proper drug and dosing, the chance of becoming seizure free with subsequent drugs is less than 2 percent. These children are placed in the intractable category. Persistent seizures, especially in early childhood, have a detrimental effect on cognitive and social development and on quality of life. The longer a child has seizures, the greater the damage to the brain.”

Epidemiological information is also lacking in Nicaragua, which precludes population-based healthcare planning and prioritization. “The healthcare system in Nicaragua is well organized and has been recognized by the World Health Organization for its success in following recommendations on how to develop a public system,” Dr. Funke says. “They’ve been extremely successful in the past 20 years in reducing infant mortality, for instance, but they don’t have much in the way of data for epilepsy. We’d like

to help them gather the meaningful epidemiological data they need to develop national treatment guidelines for children with epilepsy.”

The two physicians plan to return for a weeklong visit every four months to see patients, consult with their Nicaraguan colleagues and further develop the inter-institutional collaboration. “At this point, we’ve gotten our feet wet and are pleased with the progress we’re making,” Dr. Von Allmen says. “Many of our colleagues in the American pediatric epilepsy community are working to develop programs in Latin America and the Caribbean. We hope to work with them to gather epidemiological data that will benefit the region.”

Both physicians are impressed with the knowledge base in Managua. “Despite poverty, the families are very knowledgeable about their children, extremely observant of their condition and very involved in their care. All are very grateful for the care we provide,” she says. “Even though they have limited resources, the residents are passionate about taking care of these kids and learning more about how to treat epilepsy. It’s been a very rewarding experience.”

Dr. Funke agrees. “The enthusiasm of the residents is infectious,” he says. “They’re well educated despite having much less access to educational resources than we have in the United States. Here, we have advanced imaging and other studies to rely on in making diagnoses and treatment decisions. There, they do things more in the old way, relying on their experience, observation and intuition. We have much to learn from each other.”



**The pediatric epilepsy surgery team in Nicaragua:** (left to right) Dr. Ugama, Hospital Alemán-Nicaragüense (HAN); Dr. Yurisia Zelaya, HAN; Dr. Gretchen Von Allmen, McGovern Medical School; Lisa Caballero, McGovern Medical School; Dr. Lester Espinoza, HAN; Dr. Michael Funke, McGovern Medical School; and Dr. Ericka Arroliga, Universidad Nacional Autónoma de Nicaragua.

# HELPING OUT *in* HAITI: A HOUSTON SURGICAL TEAM TRAVELS SOUTH *to* TREAT CHILDREN *with* HYDROCEPHALUS

**I**n January, a 13-member team from the Memorial Hermann Mischer Neuroscience Institute, Children's Memorial Hermann Hospital and McGovern Medical School at UTHealth made their annual medical mission trip to Haiti, where they spent five days caring for children with hydrocephalus. The team of pediatric neurosurgeons, pediatric anesthesiologists and nurses travels to Haiti every holiday season in conjunction with Project Medishare, a Miami-based nonprofit organization with a 20-plus-year history of working to improve health conditions for the people of Haiti.

---

**“BECAUSE HAITI HAS NO FORMALLY TRAINED PEDIATRIC NEUROSURGEONS, WE HELP PROVIDE PEDIATRIC NEUROSURGICAL CARE, ROTATING WITH OTHER PHYSICIAN GROUPS WHO COLLABORATE WITH PROJECT MEDISHARE SO THAT THE HOSPITAL HAS PEDIATRIC NEUROSURGERY COVERAGE AS OFTEN AS POSSIBLE.”**

---

As with all mission trips, the team had to orient themselves quickly, working at Hospital Bernard Mevs in Port-au-Prince. “We hit the ground running,” says Katrina Meshell, RN, a pediatric neurosurgery operating room nurse at Children's Memorial Hermann Hospital. “It helps that we've made the trip several times, and even though there are always new people with us, we work together well as a team. The doctors see patients in clinic while we set up our two ORs with supplies we've collected from our hospital's mission bins. There's a lot of camaraderie.”

The Texas team was met by Project Medishare's Margaret “Maguy” Rochelin, RN, who arranges for 60 to 70 children and their families to come to the clinic for evaluation on the first day. The team spends long hours in the OR on days two through four, performing eight surgeries - usually endoscopic third ventriculostomies - on each of the three days. On the final day, physicians see patients on the hospital wards and give follow-up care plans to Rochelin.

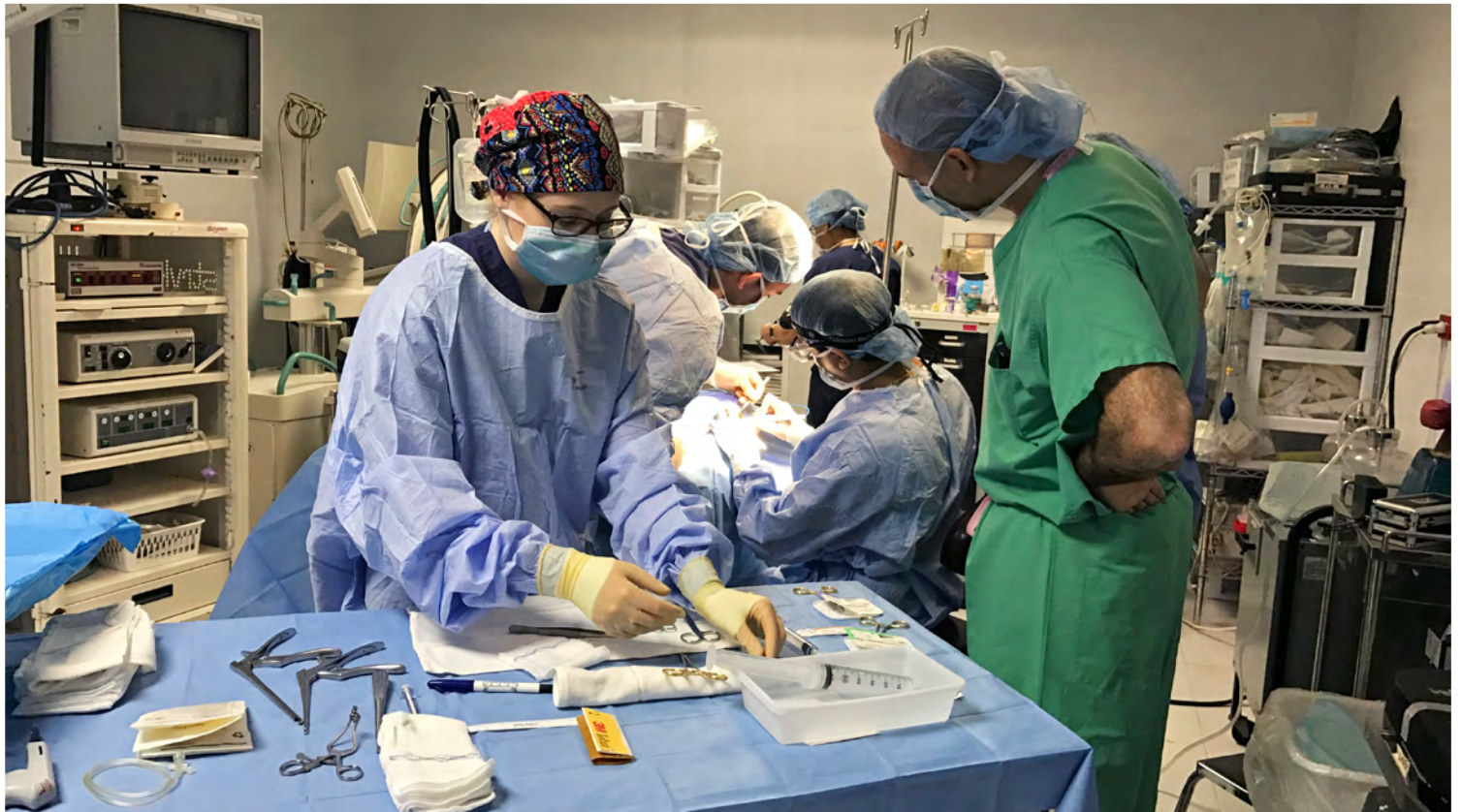With its long history in Haiti, Project Medishare mobilized the first medical team on the ground just 12 hours after the Caribbean country's devastating 2010 earthquake. Through medical volunteers, the organization treats more than 180,000 people annually. The contributions of physicians and staff members affiliated with Memorial Hermann and UTHealth were generously supported by a gift from Dick Bassett to the Memorial Hermann Foundation. Bassett and his colleague, Debbie Davis, accompanied the team to Haiti.

Among the medical professionals on the trip was pediatric neurosurgeon Manish N. Shah, M.D., who received the 2017 Young Neurosurgeons Committee Public Service Citation from the American Association of Neurological Surgeons on April 25. The citation honors the extraordinary efforts of a young neurosurgeon who, outside the traditional art and science of neurosurgery, has served the public in a way that brings greater benefit to mankind and honor to the specialty.

This year's mission to Haiti was Dr. Shah's fifth. He made his first trip in 2011 as a senior resident at Washington University School of Medicine, accompanying his mentor, David Limbrick, M.D., the 2012 recipient of the AANS Young Neurosurgeons Committee Public Service Citation. He returned twice in 2014 and again in 2015.

“It's such a privilege to provide care for the children of Haiti and it's incredibly meaningful to receive recognition from my peers for the work we do,”





says Dr. Shah, who is the Director of Pediatric Spasticity and Epilepsy Surgery. “Knowing that Dr. Limbrick also received the award makes me feel that I’m on the right track with my career, helping children with hydrocephalus in Houston and in Haiti.”

In addition to Katrina Meshell, RN, and Dr. Shah, the team included David Sandberg, M.D., FAANS, FACS, FAAP, director of pediatric neurosurgery at Children’s Memorial Hermann Hospital and Mischer Neuroscience Institute, who holds the Dr. Marnie Rose Professorship in Pediatric Neurosurgery at UTHealth; anesthesiologist Maria Matuszczak, M.D., professor and director of pediatric anesthesia at McGovern Medical School; Ranu Jain, M.D., associate professor of anesthesiology; neurosurgery residents Dan Monsivais, M.D., and Jessica Stark, M.D.; anesthesiology resident Shirley Cruz Beltran, M.D.; and nurses Linda Mobley, RN, Jenna Tally, RN, and Jenny Ermis, RN.

“Because Haiti has no formally trained pediatric neurosurgeons, we help provide pediatric neurosurgical care, rotating with other physician groups

who collaborate with Project Medishare so that the hospital has pediatric neurosurgery coverage as often as possible,” Dr. Sandberg says. “Our team works very hard for five days. We prepare for the trip together and bring in all our own surgical supplies and equipment. To do eight surgeries in a day you have to be incredibly efficient. Everyone pitches in and does whatever is needed to help these kids. It’s always a very rewarding experience.”

While in Haiti, Dr. Sandberg and Dr. Shah worked with Yudy Lafortune, M.D., a Haitian-trained general surgeon at Hospital Bernard Mevs who is learning to perform basic neurosurgical procedures with John Ragheb, M.D., at Miami Children’s Hospital. “Yudy is a good surgeon and a good doctor,” Dr. Shah says. “We hope eventually to be able to train others in a long-term effort to improve pediatric neurosurgical care in Haiti. These kids have a tremendous need. Many have very large heads – something we don’t see in the United States because we treat hydrocephalus much earlier. If untreated, the condition leads to languishment and death after years of

**Each year a team led by Dr. David Sandberg (right front) travels to Haiti to provide care for children with hydrocephalus.**

extreme challenges in their care. By treating these children, we massively improve the quality of life of the child and family.”

Dr. Matuszczak, who has participated in many medical missions and is fluent in French, helped with translation. “We manage difficult cases we normally don’t see in the western world, and yet our team works together as if we do this every day. For me, it’s always about making sure the anesthesia is as safe as we provide at home. Making all the right decisions for the treatment of these critically ill children takes incredible teamwork from all sides.”

Katrina Meshell has been making the Haiti trip since Dr. Sandberg first invited her four years ago. “It’s humbling and rewarding, and a real eye-opener that makes me appreciate everything we have here in Houston. The kids are very malnourished and their families are so grateful. It’s so much work, but I haven’t been able to walk away. It’s something I want to do and need to do. I plan to go back.”

# RESEARCH

## Two Novel Studies Seek to Improve Outcomes in Children with Malignant Fourth Ventricular Brain Tumors

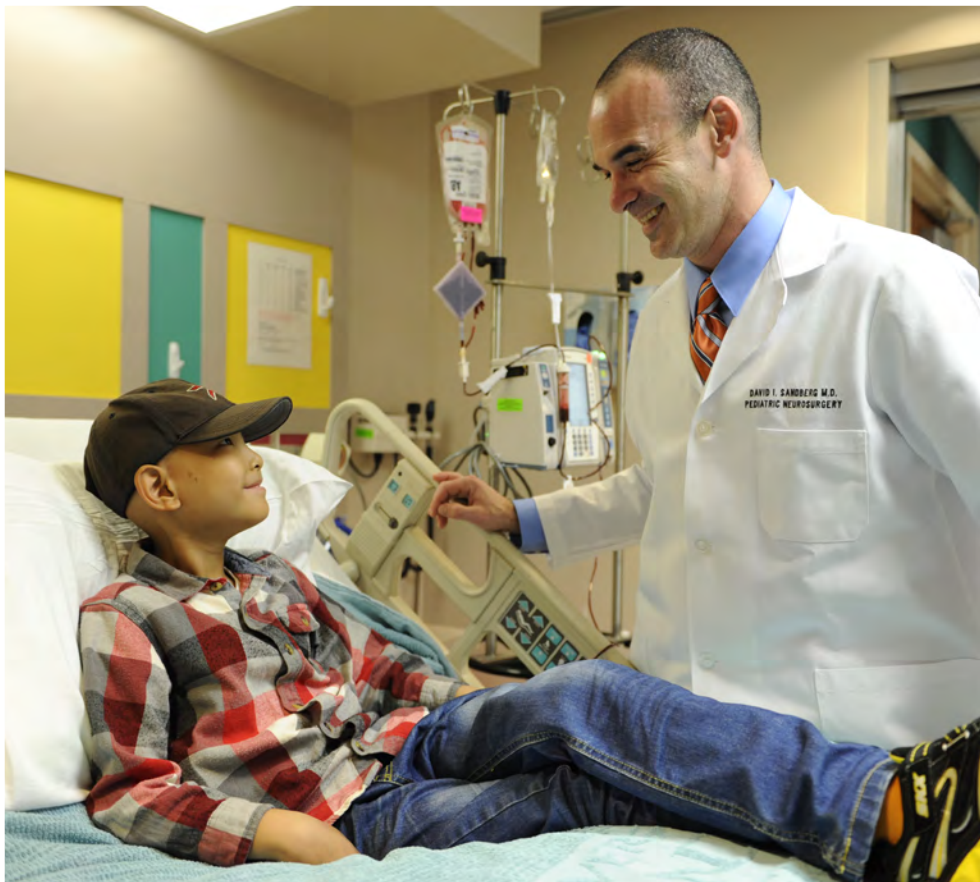The current outlook for children with recurrent malignant brain tumors originating from the posterior fossa is extremely poor. Most clinical trials offer systemic chemotherapy or re-irradiation, both of which can have a variety of side effects and most often fail in children with recurrent tumors. Two new single-center trials under way at Children's Memorial Hermann Hospital and McGovern Medical School are investigating novel therapies with the potential to improve outcomes for children with fourth ventricular brain tumors while avoiding systemic toxicity.

Conducted by David Sandberg, M.D., FAANS, FACS, FAAP, professor and director of pediatric neurosurgery at Children's Memorial Hermann Hospital, the Memorial Hermann Mischer Neuroscience Institute and UTHealth, the first trial, "A Combination Intraventricular Chemotherapy Pilot Study," is investigating methotrexate and etoposide infusions into the fourth ventricle in children with recurrent posterior fossa brain tumors. The trial is open to patients age 1 to 21 with recurrent medulloblastoma, recurrent ependymoma and recurrent atypical teratoid/rhabdoid tumors involving the brain and/or spine.



**DAVID SANDBERG, M.D., FAANS, FACS, FAAP**  
 Director, Pediatric Neurosurgery; Professor and Chief, Division of Pediatric Neurosurgery; Dr. Mamie Rose Professorship in Pediatric Neurosurgery  
 McGovern Medical School at UTHealth

"Despite advances in pediatric neuro-oncology, we're still seeing too many children die of malignant brain tumors, and the treatments currently available are not satisfactory for children," says Dr. Sandberg, who holds the Dr. Marnie Rose



Professorship in Pediatric Neurosurgery at UTHealth. "Many suffer extreme toxicity from chemotherapy and radiation, and I believe we can do better. Novel approaches are needed to improve treatment outcomes."

The primary objective of the new trial is to determine if combination intraventricular infusions of two agents, methotrexate and etoposide, are safe and can be infused without neurological toxicity. The secondary objective is to assess the antitumor activity of these infusions, in the hope that the infusions will yield even more robust treatment responses than those observed in the previous single-agent trials.

The second pilot study, "Infusion of 5-Azacytidine (5-AZA) into the Fourth Ventricle or Resection Cavity in Children with Recurrent Posterior Fossa Ependymoma," is also open for enrollment to patients age 1 to 21.

"5-AZA is a DNA methylation inhibitor that has been infused in non-human primates with no neurological toxicity, while achieving substantial and sustained cerebrospinal fluid (CSF) levels," Dr.

**Through innovative clinical trials, Dr. David Sandberg is working to improve treatments for children with malignant brain tumors.**

Sandberg says. "Recent studies have demonstrated that DNA methylation inhibitors are logical therapeutic candidates for ependymomas originating in the posterior fossa. Our goals are to establish the safety of direct administration of 5-AZA into the fourth ventricle and also hopefully demonstrate the clinical efficacy of these infusions."

Both clinical trials build on two previous recent trials conducted at Children's Memorial Hermann Hospital and UTHealth, in which Dr. Sandberg demonstrated that repeated infusions of methotrexate into the fourth ventricle are well tolerated and do not cause new neurological deficits or other serious adverse events. "We have also demonstrated that some patients, all of whom had recurred despite surgery, radiation and chemotherapy, have a response to treatment with decreased tumor burden after the infusions," he says.

Patients enrolled in the studies will undergo surgical placement of a ventricular catheter into the fourth ventricle or posterior fossa resection cavity with simultaneous surgical resection of recurrent tumor as indicated. Safety will be assessed through serial neurological examinations and MRI scans, and treatment response will be assessed via MRI scans of the brain and spine as well as lumbar punctures to assess CSF cytology.

Each of the two studies will enroll an estimated 10 patients. For questions about the studies or more information about enrollment, contact Marcia Kerr, RN, at [marcia.l.kerr@uth.tmc.edu](mailto:marcia.l.kerr@uth.tmc.edu) or by phone at 713.500.7363.

### **In the Lab: Researchers Prepare to Test a Novel High-resolution Near-infrared Functional Brain Imaging System in Pediatric Patients**

Using military-based technology, researchers at McGovern Medical School and Children's Memorial Hermann Hospital are developing a high-resolution near-infrared imaging platform with the capability to acquire hundreds of measurements simultaneously from the brains of infants and children - without ionizing radiation or the need for sedation. The novel method uses functional near-infrared spectroscopy and diffuse optical tomography (fNIRS-DOT), a combination that offers excellent temporal and spatial resolution for the entire brain, and may one day change the way physicians manage children with spasticity, epilepsy and other neurological disorders.

"When we scan a patient at rest with MRI, we can see complex, intricate patterns of spontaneous activity and watch different parts of the brain activate and deactivate over time," says Manish N. Shah, M.D., who is the Director of Pediatric Spasticity and Epilepsy Surgery. "Over the past 10 years, we've gathered a great deal of meaningful information about the way these different brain regions interact spontaneously at rest.

For instance, when we correlate spontaneous oscillations of the blood oxygen level-dependent resting state MRI signals among brain regions, we can distinguish resting state functional networks."



**MANISH N. SHAH, M.D.**

*Director, Pediatric Spasticity and Epilepsy Surgery  
Assistant Professor, Division of Pediatric Neurosurgery  
McGovern Medical School at UTHealth*

These networks are crucial to neuroscientists' understanding of the healthy adult brain, including the default mode network that modifies the brain's model of the world as a basis for prediction. Although brain MRI scans can illuminate resting functional networks in children, pediatric patients often require sedation, which makes investigation of brain function during actual disordered movements impossible.

"Of the various techniques we use to measure brain activation and deactivation, MRI is safe and has great resolution - you can see which regions of the brain are functioning," says Dr. Shah, an assistant professor in the department of Pediatric Surgery at McGovern Medical School. "PET has good spatial resolution but requires the use of a radioactive dye, and both PET and MRI have poor temporal resolution. They can show how different parts of the brain activate and deactivate over time and interact with each other. We call this functional connectivity analysis, and the way it's usually done is by taking a seed region, for example in the left motor cortex, and extracting out a time course of the way the activity fluctuates up and down. Then we test how well other parts of the brain correlate with that time course. But for low-motion MRI studies, young kids usually need sedation, which prompted us to search for an accurate imaging system that could give us good spatial and temporal resolution during movement."

Aware of her pioneering work with near-infrared fluorescence optical imaging and tomography for molecular

imaging, Dr. Shah approached chemical engineer Eva Sevick, Ph.D., professor and Kinder Distinguished Chair of Cardiovascular Research, and biomedical optical engineer Banghe Zhu, Ph.D., at the Brown Foundation Institute of Molecular Medicine (IMM) for the Prevention of Human Diseases. Dr. Sevick directs the IMM Center for Molecular Imaging and leads a research team active in preclinical, small animal imaging with nuclear and optical techniques, and together with several clinical and basic science faculty, translates near-infrared fluorescence imaging into clinical applications. "We developed this incredible technology for near-infrared imaging using fluorescence dyes in humans, and immediately saw an opportunity to take a step backward and use the same technology without the fluorescence to capture brain images in children," Dr. Sevick says. "We hypothesized that using the same instrumentation without the fluorescence filters would allow the technology to move even faster so that children and babies wouldn't require sedation during imaging. Near-infrared light propagates through several centimeters of tissue. Because it's non-ionizing with no exposure to radioactivity and requires no administration of a contrast agent, we can image children repeatedly."



**EVA SEVICK, Ph.D.**

*Professor, Director, Brown Foundation Institute of Molecular Medicine for the Prevention of Human Diseases  
Kinder Distinguished Chair of Cardiovascular Research*

Over the past few years, Dr. Sevick has used near-infrared fluorescence to visualize the workings of the lymphatic system in head and neck cancer patients with Ron Karni, M.D., chief of the division of Head and Neck Surgical Oncology in the department of Otorhinolaryngology at McGovern Medical School. Working with pediatric plastic surgeon Matthew Greives, M.D., an assistant professor in the department of Pediatric Surgery,

she put the technology to use in children with vascular and lymphatic malformations. The results of the Sevick-Greives collaboration, in which they successfully imaged the lymphatics of a baby sitting on a lap, were published in the April issue of *Pediatrics*, with an e-publication released in March.

“With Dr. Shah we’ve changed the format to measure brain oxygenation status and map oxygenated and deoxygenated hemoglobin,” Dr. Sevick says. “Dr. Zhu built the device – a highly sensitive fNIRS-DOT imaging system with a military-grade, night-goggle technology coupled to a charge-coupled device camera that can probe the brain’s default mode network in infants and children. We have a little more instrumentation to engineer and hope to be ready to test it in humans in the next six months. At the Center our goal is to make the technologies work effectively for efficient implementation in clinical studies. Dr. Shah’s goal is to improve quality of life for his patients. Through the teamwork of these forward-thinking clinicians and our inventive engineers, we’re building a bridge from the lab to the bedside.”

Dr. Shah believes that by transmitting near-infrared light through the thinner skulls of infants and children, they will be able to image oxy and deoxy hemoglobin at least 4 centimeters deep – and perhaps even deeper. “At the present, patients have to remain motionless while confined in a scanner,” he says. “Here, we put a cap on a patient, who can watch TV, read or check email while we collect the data. As soon as we’re done tuning up the instrumentation, we’ll start collecting data from normal people, followed by data collection on patients with epilepsy and cerebral palsy. We hope it will lead to better diagnosis of patients with these neurological disorders, which in turn will tell us which procedures are likely to be successful in treating specific patients. Our ultimate goal is to one day improve the way we provide care for these children.”

## NEWS of NOTE

### Dr. Ian Butler Receives Regents’ Outstanding Teaching Award



**IAN BUTLER, M.D.**

*Professor, Department of Pediatrics; Distinguished Chair in West Syndrome Research; Director, Division of Child and Adolescent Neurology  
McGovern Medical School at UTHealth*

Ian Butler, M.D., is among the 2016 recipients of The University of Texas System Regents’ Outstanding Teaching Awards, presented annually in recognition of faculty at the eight academic and six health institutions that comprise the UT System. The award is the highest honor bestowed by the Board of Regents.

Dr. Butler earned his medical degree from the University of Adelaide, Australia. He completed a residency at the Royal Children’s Hospital in Melbourne, Australia, and a fellowship at Johns Hopkins Hospital in Baltimore.

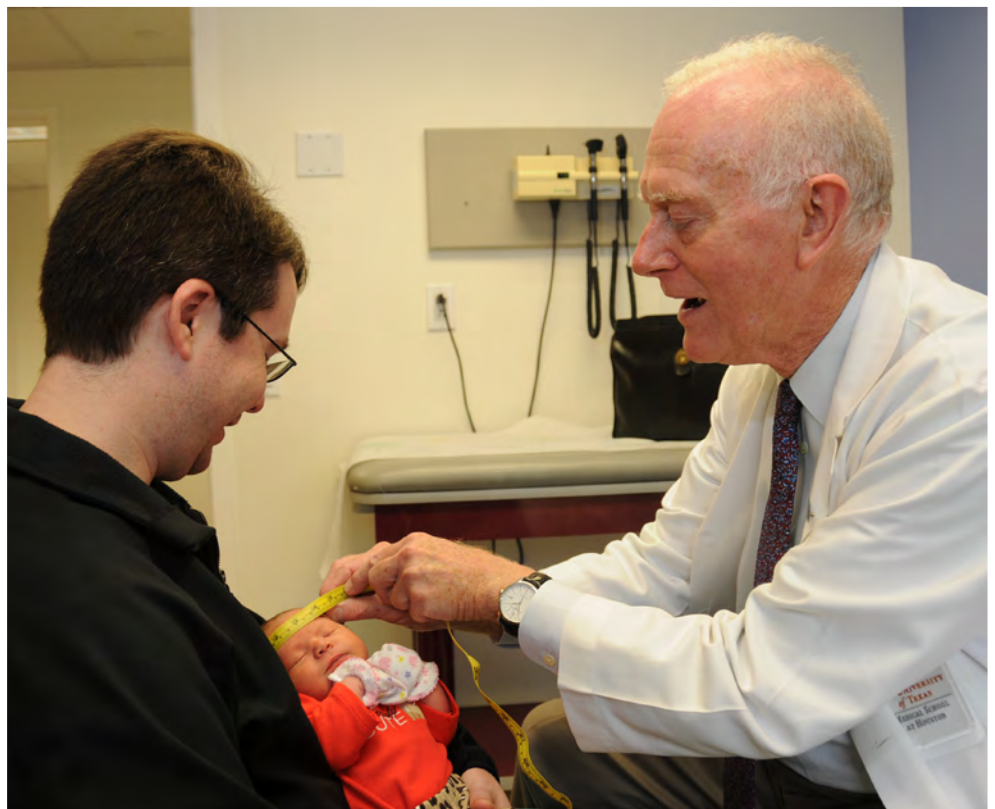Board certified in psychiatry and neurology, Dr. Butler is a fellow of the Royal Australasian College of Physicians

(FRACP). His primary clinical interests are movement disorders, neuromuscular disorders and dysautonomia. He treats patients from birth to 25 years of age.

In addition to his clinical practice, Dr. Butler serves as director of the division of Child and Adolescent Neurology and is a professor in the departments of Pediatrics, Neurology and Neurobiology/Anatomy at McGovern Medical School at UTHealth, where he is the Distinguished Chair in West Syndrome Research. He is a staff neurology consultant at the Shriners Hospital for Children in Houston. He is widely published and has been invited to lecture and participate in symposia at regional, national and international medical conferences.

Dr. Butler is also a member of the Tourette Syndrome Association of Greater Houston’s Medical Advisory Board and serves on the editorial boards of several professional journals. He has been listed repeatedly by Woodward and White as

**Dr. Ian Butler, a 2016 winner of the Regents’ Outstanding Teaching Award, treats patients from birth to 25 years of age.**



one of The Best Doctors in America, most recently in 2015.

The Regents' recognition carries a monetary award of \$25,000, among the largest rewards in the nation for outstanding faculty performance. Given the depth and breadth of talent across the UT System, the awards program is one of the nation's most competitive. Faculty members undergo a series of rigorous evaluations by students, peer faculty and external reviewers. The review panels consider a range of activities and criteria in their evaluations of a candidate's teaching performance, including classroom expertise, curricula quality, innovative course development and student learning outcomes.

Established by the Board of Regents in 2008, the Regents' Outstanding Teaching Awards complement a broad range of system-wide efforts that underscore the Board of Regents' commitment to ensuring that the UT System is a place of intellectual exploration and discovery, educational excellence and unparalleled opportunity.

### Dr. Manish N. Shah Named a Texas Super Doctors Rising Star



**MANISH N. SHAH, M.D.**

Director, Pediatric Spasticity and Epilepsy Surgery  
Assistant Professor, Division of Pediatric Neurosurgery  
McGovern Medical School at UTHealth

Manish N. Shah, M.D., a pediatric neurosurgeon affiliated with Children's Memorial Hermann Hospital and the Memorial Hermann Mischer Neuroscience Institute at the Texas Medical Center, has been selected by his peers as a Super Doctors® Rising Star in Texas. Following an extensive independent nomination and research process, the results were published in the June 2016 issue of *Texas Monthly* magazine.

**The 2017 Run for the Rose team from Children's Memorial Hermann Hospital and Mischer Neuroscience Institute helped raise awareness and funds for brain cancer research.**



Dr. Shah directs the Texas Comprehensive Spasticity Center at Children's Memorial Hermann Hospital, Mischer Neuroscience Institute and McGovern Medical School. He is also director of pediatric spasticity and epilepsy surgery and runs a laboratory where researchers use advanced neuroimaging techniques to investigate basic brain function in children.

"I am proud to be recognized along with so many respected individuals in the Houston area," Dr. Shah says. "I have the privilege of helping children achieve a better quality of life in the face of debilitating disease – a reward in itself."

Dr. Shah is an assistant professor in the department of Pediatric Neurosurgery at McGovern Medical School and the leading neurosurgeon in the area for selective dorsal rhizotomy. He is fellowship trained in pediatric neurosurgery with special expertise in the surgical management of spasticity and dystonia in children, and performs selective dorsal rhizotomies and baclofen pump placement using

advanced techniques. He is also an expert in pediatric epilepsy, craniofacial surgery and craniocervical spine surgery.

### Report on the 2017 Run for the Rose

Children's Memorial Hermann Hospital and the Memorial Hermann Mischer Neuroscience Institute were proud sponsors of the 15th Annual Run for the Rose, held Sunday, April 2, 2017, at NRG Park in Houston. Participants, ranging in age from 2 months to 102 years of age, included patients, family members and supporters committed to raising awareness and funds supporting brain cancer research at The University of Texas MD Anderson Cancer Center, Children's Memorial Hermann Hospital and McGovern Medical School at UTHealth.

The run is sponsored annually by the Dr. Marnie Rose Foundation, which has supported brain cancer research and pediatric health initiatives in Houston since 2003. In 2016, the Foundation made a donation of \$150,000 – funds raised through the Run for the Rose, the Brain Power 5K in Austin and memorials and tributes made throughout the year – to Children's Memorial Hermann Hospital. To date, the Dr. Marnie Rose Foundation has given more than \$5.3 million to Children's Memorial Hermann Hospital, MD Anderson Cancer Center and McGovern Medical School. These funds also support the Dr. Marnie Rose Professorship in Pediatric Neurosurgery at UTHealth, held by David Sandberg, M.D., FAANS, FACS, FAAP.



# SELECTED PUBLICATIONS

Austin MT, Hamilton E, Zebda D, Nguyen H, Eberth JM, Chang Y, Elting LS, Sandberg DI. Health Disparities and Impact on Outcomes in Children with Primary Central Nervous System Solid Tumors.” *Journal of Neurosurgery:Pediatrics*. 2016;19:1-9.

Bagi AI, Bowyer SM, Kirsch HE, Funke ME, Burgess RC; ACMEGS Position Statement Committee. American Clinical MEG Society (ACMEGS) Position Statement #2: The Value of Magnetoencephalography (MEG)/Magnetic Source Imaging (MSI) in Noninvasive Presurgical Mapping of Eloquent Cortices of Patients Preparing for Surgical Interventions. *Journal of Clinical Neurophysiology*. 2017 Jan 5. doi: 10.1097/WNP.0000000000000366. [Epub ahead of print]

Barr RM, Khan SA, Shah MN, Roy S, Teichgraber JF, Greives MR. Cervical Instability in Pierre Robin Sequence: An Addition to the Algorithm. *J Craniofac Surg*. Oct;27(7):1674-1676.

Bonfante E, Koenig MK, Adejumo RB, Perinjelil V, Riascos RF. The neuroimaging of Leigh syndrome: case series and review of the literature. *Pediatric Radiology*. 2016;46:443-451.

Chao YH, Robak LA, Xia F, Koenig MK, Adesina A, Bacino CA, Scaglia F, Bellen JH, Wangler MF. Missense variants in the middle domain of DNMI1 in cases of infantile encephalopathy alter peroxisomes and mitochondria when assayed in *Drosophila*. *Human Molecular Genetics*. 2016;25:1845-1856.

Chong DJ, Dugan P, \*EPGP Investigators. Ictal fear: Associations with age, gender, and other experiential phenomena. *Epilepsy & Behavior*. 2016; 62:153-8.

\*Epi4K consortium, EPGP Investigators. Ultra-rare genetic variation in common epilepsies: a case-control sequencing study. *Lancet Neurology*. 2017; 16: 135-143.

Farach LS, Northrup H. KIAA2022 Nonsense Mutation in a Symptomatic Female. *Am J Med Genet A*. 2016 Mar;170(3):703-6. doi: 10.1002/ajmg.a.37479. Epub 2015 Nov 17.

Fountain MD, Aten E, Cho MT, Juusola J, Walkiewicz MA, Ray JW, Xia F, Yang Y, Graham BH, Bacino CA, Potocki L, van Haeringen A, Ruivenkamp CA, Mancias P, Northrup H, Kukolich MK, Weiss MM, van Ravenswaaij-Arts CM, Mathijssen IB, Levesque S, Meeks N, Rosenfeld JA, Lemke D, Hamosh A, Lewis SK, Race S, Stewart LL, Hay B, Lewis AM, Guerreiro RL, Bras JT, Martins MP, Derksen-Lubsen G, Peeters E, Stumpel C, Stegmann S, Bok LA, Santen GW, Schaaf CP. The phenotypic spectrum of Schaaf-Yang syndrome: 18 new affected individuals from 14 families. *Genet Med*. 2016 May 19. doi: 10.1038/gim.2016.53. [Epub ahead of print]

Fu KJ, Barr RM, Shah MN, Fletcher SA, Sandberg DI, Teichgraber JF, Greives MR. An Outcomes Comparison Between Autologous and Alloplastic Cranioplasty in the Pediatric Population. *Journal of Craniofacial Surgery*. 2016;27(3):593-597.

Gu JL, Johnson A, Kerr M, Moise KJ, Bebbington MW, Pedroza C, Sandberg DI. Correlating Prenatal Imaging Findings of Fetal Ventriculomegaly with the Need for Surgical Intervention in the First 3 Months After Birth. *Pediatric Neurosurgery*. 2017;52(1):20-25.

Hunold A, Funke ME, Eichardt R, Stenroos M, Haueisen J. EEG and MEG: sensitivity to epileptic spike activity as function of source orientation and depth. *Physiological Measurement*. 2016 Jul;37(7):1146-62.

Koenig MK. Friedreich's Ataxia. *Mitochondrial Case Studies: Underlying Mechanisms and Diagnosis 2016*. Elsevier, San Diego, California.

Koenig MK. Nitric oxide deficiency triggering stroke-like episodes-reply. *JAMA Neurology*. 2016;73:1030.

Koenig MK, Emrick L, Karaa A, Korson M, Scaglia F, Parikh S, Goldstein A. Recommendations for the Management of Stroke-like Episodes in Patients with Mitochondrial Encephalomyopathy, Lactic Acidosis, and Stroke-like Episodes. *JAMA Neurology*. 2016;73:591-594.

Koenig MK, Grant L. Neuropathy, ataxia, and retinitis pigmentosa (NARP). *Mitochondrial Case Studies: Underlying Mechanisms and Diagnosis*. 2016. Elsevier, San Diego, California.

Lalani SR, Liu P, Rosenfeld JA, Watkin LB, Chiang T, Leduc MS, Zhu W, Ding Y, Pan S, Vetrini F, Miyake CY, Shinawi M, Gambin T, Eldomery MK, Akdemir ZH, Emrick L, Wilani Y, Schelley S, Koenig MK, Memon N, Farach LS, Coe BP, Azamian M, Hernandez P, Zapata G, Jgangiani SN, Muzny DM, Lotze T, Clark G, Wilfong A, Northrup H, Adesina A, Bacino CA, Scaglia F, Bonnen PE, Crosson J, Duis J, Maegawa GH, Coman D, Inwood A, McGill J, Boerwinkle E, Graham B, Beaudet A, Eng CM, Hanchard NA, Xia F, Orange JS, Gibbs RA, Lupski JR, Yang Y. Recurrent muscle weakness with rhabdomyolysis, metabolic crises, and cardiac arrhythmia due to bi-allelic TANGO2 mutations. *The American Journal of Human Genetics*. 2016;98:347-357.

Mattioli F, Schaefer E, Magee A, Mark P, Mancini GM, Dieterich K, Von Allmen G, Alders M, Coutton C, van Slegtenhorst M, Vieville G, Engelen M, Cobben JM, Juusola J, Pujol A, Mandel JL, Piton A. Mutations in Histone Acetylase Modifier BRPF1 Cause an Autosomal-Dominant Form of Intellectual Disability with Associated Ptosis. *Am J Hum Genet*. 2017;100(1):105-116.

Nguyen MP, Lupo PJ, Northrup H, Morrison AC, Cirino PT, Au KS. Maternal gene-micro-nutrient interactions related to one-carbon metabolism and the risk of myelomeningocele among offspring. *Birth Defects Res A Clin Mol Teratol.* 2016 Jul 7. doi: 10.1002/bdra.23538. [Epub ahead of print]

Parikh S, Karaa A, Goldstein A, Ng YS, Gorman G, Feigenbaum A, Christodoulou J, Haas R, Tarnopolsky M, Dimmock D, Feyma T, Koenig MK, Mundy H, Niyazov D, Saneto RP, Wainwright MS, Wusthoof C, McFarland R, Scaglia F. Solid organ transplantation in primary mitochondrial disease: proceed with caution. *Molecular Genetics and Metabolism.* 2016;118:178-184.

Rodin EA, Taulu SJ, Funke ME, Johnson MB, Bornfleth H, Constantino TM. Magnetoencephalographic Infraslow Activity: A Feasibility Study. *Journal of Clinical Neurophysiology.* 2016 Aug;33(4):350-8.

Rosnau K, Hashmi SS, Northrup H, Slopis J, Noblin S, Ashfaq M. Knowledge and Self-Esteem of Individuals with Neurofibromatosis Type 1 (NF1). *J Genet Couns.* 2016 Nov 4. Epub ahead of print.

Sahin M, Henske EP, Manning BD, Ess KC, Bissler JJ, Klann E, Kwiatkowski DJ, Roberds SL, Silva AJ, Hillaire-Clarke CS, Young LR, Zervas M, Mamounas LA. Tuberous Sclerosis Complex Working Group to Update the Research Plan. *Advances and Future Directions for Tuberous Sclerosis Complex Research: Recommendations From the 2015 Strategic Planning Conference.* *Pediatr Neurol.* 2016 Apr 2. doi: 10.1016/j.pediatr-neurol.2016.03.015. [Epub ahead of print]

Sandberg DI. Endoscopic Resection of Intraventricular Brain Tumors in Children. *World Neurosurgery.* 2016;89:708-9.

Sandberg DI, Kerr ML. Ventricular Access Device Placement in the Fourth Ventricle to Treat Malignant Fourth Ventricle Brain Tumors: Technical Note. *Child's Nervous System.* 2016;32(4):703-7.

Shah MN\*, Smith SE\*, Dierker DL, Herbert JP, Coalson TS, Bruck BS, Zipfel GJ, Van Essen DC, Dacey RG. The relationship of cortical folding and brain arteriovenous malformations. *Neurovascular Imaging.* 2016 November 22; 2(1):13. \*Co-first authors

Shah RH, Northrup H, Hixson JE, Morrison AC, Au KS. Genetic association of the glycine cleavage system genes and myelomeningocele. *Birth Defects Res A Clin Mol Teratol.* 2016 Oct;106(10):847-853. doi: 10.1002/bdra.23552.

Srihawan C, Castelblanco RL, Salazar L, Wootton SJ, Aguilera E, Ostrosky-Zeichner L, Sandberg DI, Choi H, Lee K, Kitagawa R, Tandon N, Hasburn R. Clinical Characteristics and Predictors of Adverse Outcome in Adult and Pediatric Patients with Healthcare-Associated Ventriculitis and Meningitis. *Open Forum Infectious Diseases.* 2016;13(3):77.

Winawer MR, Shih J, Beck ES, Hunter JE, Epstein MP; \*EPGP Investigators. Genetic effects on sleep/wake variation of seizures. *Epilepsia.* 2016; 57(4):557-65.

Yang J, Bassuk AG, Merl-Pham J, Hsu CW, Colgan DF, Li X, Au KS, Zhang L, Smemo S, Justus S,

Nagahama Y, Grossbach AJ, Howard MA 3rd, Kawasaki H, Feldstein NA, Dobyns WB, Northrup H,

Hauck SM, Ueffing M, Mahajan VB, Tsang SH. Catenin delta-1 (CTNND1) phosphorylation controls the mesenchymal to epithelial transition in astrocytic tumors. *Hum Mol Genet.* 2016 Aug 11. pii: ddw253. [Epub ahead of print]

Zhu B, Shah MN, Godavarty A, Sevick E. Brain connectivity in joint attention skills and an intensified CCD camera based NIRS and imaging system. *Biomedical Optics 2016, OSA Technical Digest (online) (Optical Society of America, 2016), paper JW3A.52.*

*\*EPGP Investigators: Bassel Abou-Khalil, Brian K Alldredge, Dina Amrom, Eva Andermann, Frederick Andermann, Jocelyn F. Bautista, Samuel F Berkovic, Judith Bluvstein, Alex Boro, Gregory D Cascino, Damian Consalvo, Patricia Crumrine, Orrin Devinsky, Dennis Dlugos, Michael P Epstein, Miguel Fiol, Nathan B Fountain, Jacqueline French, Catharine Freyer, Daniel Friedman, Eric B Geller, Tracy Glauser, Simon Glynn, Kevin Haas, Sheryl R Haut, Jean Hayward, Sandra L Helmers, Sucheta Joshi, Andres Kanner, Heidi E Kirsch, Robert C Knowlton, Eric H Kossoff, Rachel Kuperman, Ruben Kuzniecky, Daniel H Lowenstein, Paul V Motika, Edward J Novotny, Ruth Ottman, Juliann M Paolicchi, Jack M Parent, Kristen Park, Annapurna Poduri, Lynette G Sadleir, Ingrid E Scheffer, Renee A. Shellhaas, Elliott H Sherr, Jerry J. Shih, Shlomo Shinnar, Rani K Singh, Joseph Sirven, Michael C Smith, Joseph Sullivan, Liu Lin Thio, Anu Venkat, Eileen P.G Vining, Gretchen K Von Allmen, Judith L Weisenberg, Peter Widdess-Walsh and Melodie R Winawer.*

Memorial Hermann Health System  
7737 Southwest Freeway  
Houston, TX 77074

[childrens.memorialhermann.org/neuro](http://childrens.memorialhermann.org/neuro)  
832.325.7242

Nonprofit Org.  
U.S. POSTAGE  
**PAID**  
Permit No. 3156  
Houston, TX